

10:56 AM

MIVS 23-Gauge Pars Plana Vitrectomy Management of Complex Retinal Detachment in Eyes with Brachytherapy - Treated Posterior Uveal Melanoma



- Timothy G. Murray, MD, MBA
- Arnold M Markoe, MD, ScD
- Steve K Houston, MD
- Marcela Lonngi, MD

OBJECTIVE To evaluate anatomic and visual improvements, along with safety, in eyes undergoing vitrectomy with previously treated uveal melanoma

PURPOSE To determine the safety profile, visual functional improvements, and anatomic outcomes after 23 gauge MIVS pars plana vitrectomy surgery for complex retinal detachment in eyes previously treated with brachytherapy for uveal melanoma.

METHODS IRB approved, consecutive case series of 91 eyes of 91 patients undergoing 23 gauge pars plana vitrectomy (MIVS) for complex retinal detachment after 125-Iodine

brachytherapy for treated uveal melanoma between March 2008 and February 2011. All patients had documented tumor control. Mean patient age at time of vitrectomy was 65 years. All patients underwent 23 gauge MIVS, release of vitreoretinal traction including membrane peeling, vitreous cytology evaluation, direct endolaser tumor treatment, and intravitreal triamcinolone acetonide injection. All eyes were followed for resolution of retinal detachment, reduction in tumor volume, VA, IOP, and post-MIVS complications.

RESULTS Mean patient age was 65 years. MIVS surgery was performed 35 months after 125-Iodine brachytherapy (6-115 months). Retinal detachment was resolved in 84/91 patients (92%) and eyes remained stable with a mean followup of 14 months (6-40 months). Pre-MIVS VA was 20/204 and improved to 20/102 at last follow-up ($p<.0016$). 44 of 91 eyes (48%) recovered VA better than 20/40. Tumor volume decreased by 26% ($p<.0.035$). Decreased VA was associated with NVG (5%), Radiation maculopathy (85%), and radiation optic neuropathy (12%). No patient developed local ocular tumor recurrence. 91 of 91 patients were alive at last followup with 3 patients having developed metastatic disease (3/91, 3.2%). Predictors of best VA outcomes included entry level VA better than 20/100, absence of concomitant macular disease, macula sparing exudative detachment, and anterior located uveal melanoma.

CONCLUSION 23 gauge pars plana vitrectomy (MIVS) can effectively manage complex retinal detachments in eyes having undergone definitive 125-Iodine brachytherapy for uveal melanoma. VA and anatomic function were improved in virtually all treated eyes. Tumor control prior to vitrectomy intervention appears to decrease the concern for local, orbital or metastatic tumor progression associated with vitrectomy.

TAKE HOME MESSAGE 23 gauge pars plana vitrectomy (MIVS) is safe and effective in eyes with effectively treated posterior uveal melanoma.

11:04 AM

Pars Plana Vitrectomy with Medium-Term Perfluoro-n-octane for Recurrent Inferior Retinal Detachment Complicated by Proliferative Vitreoretinopathy

- Steve T. Charles, MD

OBJECTIVE To describe a series of patients with recurrent inferior retinal detachment with PVR treated with pars plana vitrectomy (PPV) and medium term perfluoro-n-octane (PFO).

PURPOSE To determine if medium term PFO has an acceptable risk benefit ratio for the management of inferior PVR.

METHODS Consecutive patients with recurrent inferior retinal detachment and grade C PVR were prospectively treated with 25-gauge PPV and postoperative “medium-term” PFO for 2-3 weeks duration (MT-PFO). All patients had subsequent PFO removal in a planned, staged procedure.

RESULTS 44 eyes of 44 patients were included. Mean follow-up was 30.71 ± 12.92 months. Successful reattachment was achieved in 86% of eyes (38/44). Re-attachment rates were statistically equivalent between eyes with and without previous scleral buckle. Reasons for re-detachment were recurrent inferior PVR (4/6) and new superior break without PVR (2/6). Additional complications observed were cataract progression requiring surgery (42%), persistent IOP elevation (36%), and transient inflammation (32%). Macula-off status ($p=0.02$) and persistent IOP elevation ($p=0.02$) were factors associated with worse visual outcome.

CONCLUSION Medium term PFO was found to be an efficacious technique for operative management of recurrent inferior retinal detachments complicated by grade C PVR. The

method of primary repair did not statistically affect reattachment rates. Transient inflammation and IOP elevation are potential complications associated with this technique. Persistent IOP elevation was associated with worse visual outcome.

TAKE HOME MESSAGE Medium term PFO is safe and effective for inferior PVR management.

11:12 AM

23-Gauge Endoscopic Vitrectomy for Complicated Retinal Diseases

- Jeffrey S. Heier, MD

OBJECTIVE Demonstrate the benefit of a 23 Gauge triple function endoscope in the management of complicated retinal disease

PURPOSE To describe the benefit of 23-gauge endoscopic vitrectomy for the surgical management of complicated retinal diseases. To review the limitations of conventional viewing systems with regards to visualization and access to retroiridal structures.

METHODS This is a retrospective review of all 23-gauge endoscopic vitrectomy cases conducted by one surgeon (JSH) at Ophthalmic Consultants of Boston, Boston, MA, between April 2009 and November 2011. Cases were identified by surgical logs. The 23-gauge triple-function endoscope (Endo Optics, Little Silver, NJ, USA) used for these cases was capable of video, illumination, and laser. Data recorded included surgical indications and outcomes. Surgical cases were recorded and qualitatively evaluated.

RESULTS 33 cases utilized the triple-function 23-gauge endoscope. Surgical indications included retinal detachment in the setting of compromised anterior segment (trauma, corneal decompensation, pupillary membrane, IOL malposition), chronic hypotony, non-clearing vitreous hemorrhage, severe endophthalmitis, and posterior tube shunt placement. Successful surgical repair was achieved in each of the above situations utilizing total endoscopic visualization without direct visualization. Successful surgical outcome was defined as retinal reattachment (15/19 cases or 79%), removal of vitreous hemorrhage with treatment of underlying cause (4/4 or 100%), resolution of chronic hypotony (2/5 or 40%), preservation of the eye with recovery of hand motions vision or better in the cases of severe endophthalmitis (1/2 or 50%), and successful placement of posterior tube shunt without complication by residual vitreous (3/3 or 100%). A larger cohort with additional cases will be presented

CONCLUSION 23-gauge endoscopic vitrectomy offers a safe and effective means of achieving surgical repair in complicated retinal diseases that would otherwise be difficult or impossible to accomplish due to visualization and/or access to retroiridal structures. This presentation will demonstrate 23-gauge endoscopic vitrectomy with surgical video and animations.

TAKE HOME MESSAGE 23-Gauge endoscopic vitrectomy can be an important addition to the retina surgeon's surgical armamentarium in the management of complicated retinal disease.

11:26 AM

Oral Fluoroquinolones and the Risk of Retinal Detachment



- David A. L. Maberley, MD, FRCS(C)

OBJECTIVE To explore the association between oral fluoroquinolone use and the risk of retinal detachment.

PURPOSE Fluoroquinolones (FQ) are a widely prescribed class of antibiotics that have been shown to interfere with collagen synthesis. Despite numerous case reports of ocular toxicity, a pharmacoepidemiologic study of their ocular safety, has not been performed. We thought to evaluate the risk of oral fluoroquinolone use on the development of retinal detachment (RD).

METHODS A nested case-control study involving all patients having seen an ophthalmologist in British Columbia (BC) between 2000 and 2007 was undertaken. BC's population receives health care through a universal provincial program. The BC Linked Health Database has longitudinal data on all 4.5 million residents in the province. RD was defined by a diagnosis code a retinal procedure within 14 days of diagnosis. Fluoroquinolone exposure was categorized as current use, 1-7 days, or 8-365

days before RD. 10 controls were selected for each case using density-based sampling and were matched on age and date of entry into cohort. Rate ratios compared RD incidence rates for FQ users vs. non-users.

RESULTS The cohort comprised 989,591 patients of which 4,384 cases of RD were identified and 43,840 controls were selected. After controlling for cataract surgery and excluding patients with endophthalmitis, current use of fluoroquinolones was strongly associated with RD risk [Adjusted rate ratio (ARR) 4.50 (95% CI: 3.56-5.70)]. Ciprofloxacin contributed the most cases of RD. Respiratory tract and GU infections were the most common indications for FQ use. The average time between prescription and RD was 4.8 days. Prior use of FQs was not associated with RD risk. The absolute increased risk of RD in current users was 4 per 10,000 person years. This translates into a population attributable risk of ~ 4% and would account for approximately 1440 cases of RD annually in the United States.

CONCLUSION After controlling for known confounders, the results of this study are consistent with an association between oral fluoroquinolone use and retinal detachment.

TAKE HOME MESSAGE There is evidence to suggest oral fluoroquinolone use increases the risk of retinal detachment.

11:34 AM

Pneumatic Retinopexy in 1000 Eyes With Rhegmatogenous Retinal Detachment: What Have We Learned?

- Thierry C. Verstraeten, MD

OBJECTIVE To review the optimal presenting features of primary rhegmatogenous retinal detachments suitable for repair using pneumatic retinopexy and optimize the success rate

PURPOSE Can the retina specialist build on his/her experience in treating the majority of primary cases of superior retinal detachment using office-based pneumatic retinopexy? Appropriate case selection can lead to a safe expansion of its usefulness and achieve a greater than 70% success rate with lower morbidity and cost.

METHODS Using a retrospective office computer record review of 3400 cases of retinal detachment (RD) (ICD: 361.00), a consecutive series of 1000 eyes treated by pneumatic retinopexy (PR) (CPT: 67110) were identified over a 10 year period (2001-2011). The male/female ratio was 62/38%. The age ranged from 16 to 92 (mean: 64) years. The follow-up period ranged 6 months to 8 years. 58 patients had a history of contralateral RD. The technique involved subconjunctival or retrobulbar xylocaine 2% anesthesia, cryotherapy of all detected breaks and lattice degeneration in detached and attached retina, betadine prep, pars plana injection of 0.5 cc of pure SF6 and AC paracentesis

RESULTS The average entry visual acuity (VA) was 20/80, with 'macula on' status in 366/1000 eyes. The lens status was phakic in 613/1000 eyes and pseudo- or aphakic in 387/1000 eyes. Primary success was defined as staying out of the operating room. In phakic eyes the 1ary success was 77% (472/613) while in pseudophakes it dropped to 62% (241/387)($p=0.01$). When undergoing PPV for failed re-attachment, the main cause was missed or new breaks (85%), persistent anterior flap traction (11%) and unknown

(4%). The single highest failure rate (45%) was seen in pseudophakic RD with macula off and the presence of inferior fluid. Scleral buckle with or without PPV was offered to the phakic failed cases (141/613) and was successful in 92%. In pseudophakes (146/387) the most common procedure was PPV alone (62%) VS PPV + buckle (38%). Some degree of PVR was seen in 48 eyes and silicone oil was used in 36 eyes. A total of 54/1000 needed 3 or more procedures. Final mean VA was 20/50 at 6 months

CONCLUSION The successful treatment of primary RD using PR in over 70% of cases renders this treatment modality attractive. It is associated with low morbidity and lower cost compared to operating room based surgical treatment. While the highest success rate is seen in phakic eyes, appropriate case selection makes this procedure attractive to a willing surgeon who is not daunted by a steep learning curve

TAKE HOME MESSAGE Pneumatic retinopexy has a greater than 70% success rate in the treatment of primary retinal detachment. In phakic eyes with single superior tear the success exceeds 80%.

11:46 AM

Optic Neuropathy Following Vitrectomy for Retinal Detachment: Clinical Features and Analysis of Risk Factors

- Alok Shawn Bansal, MD
- Jason Hsu, MD
- Sunir J. Garg, MD
- Arunan Sivalingam, MD
- James F. Vander, MD
- Mark Moster, MD
- Joseph I. Maguire, MD
- Carl D. Regillo, MD, FACS

OBJECTIVE To describe the clinical characteristics of and risk factors for optic neuropathy following pars plana vitrectomy (PPV) for macula-sparing primary rhegmatogenous retinal detachment (RRD).

PURPOSE Decreased vision after PPV can be rarely due to optic neuropathy. Although there are reports of visual field defects after PPV for macular hole, there is limited data on optic neuropathy after PPV for RRD repair. The purpose of our report is to describe the clinical features and risk factors for this rare surgical complication. We hypothesize that reduced ocular perfusion may be contributory.

METHODS We conducted a retrospective, case-control study consisting of 8 patients undergoing PPV for macula-sparing primary RRD that subsequently developed optic neuropathy between 2005 and 2011 and 25 consecutive control patients undergoing PPV for macula-sparing primary RRD. We describe the clinical features of patients with optic neuropathy following PPV for macula-sparing RRD and analyze the potential risk factors (age, gender, medical history, surgical technique, intraoperative ocular perfusion pressure, operative time) for its occurrence.

RESULTS Eight eyes of 8 patients experienced optic neuropathy following PPV for macula-sparing primary RRD. All patients had visual acuity less than 20/200 with optic nerve pallor at last follow-up. Seven of 8 patients showed relative afferent pupillary defects, and 6 of 8 patients showed visual field defects. Five of 8 (63%) demonstrated reduced ocular perfusion pressure compared to one of 25 (4%) patients in the control cohort ($p=0.004$). Additionally, patients with optic neuropathy had longer operative times compared to control ($p=0.04$).

CONCLUSION Optic neuropathy following PPV for macula-sparing primary RRD can be a rare, devastating surgical complication. Although the etiology is often unclear, reduced ocular perfusion due to intraoperative systemic hypotension may be a contributing risk factor in certain eyes.

TAKE HOME MESSAGE Although the etiology of optic neuropathy following vitreous surgery remains unknown, we report a possible association between this complication and reduced intraoperative ocular perfusion.

11:50 AM

The Minimally Invasive 25-Gauge Vitreoretinal Surgery with Perfluoropropane or Air Tamponade in the Treatment of Rhegmatogenous Retinal Detachments

- Cesare M.C. Mariotti, MD
- Francesca Viti, MD
- Andrea Saitta
- Michele Nicolai, MD

OBJECTIVE To demonstrate efficacy and safety of 25 gauge transconjunctival vitreoretinal surgery with perfluoropropane or air tamponade for the treatment of rhegmatogenous retinal detachments.

PURPOSE To assess the outcomes and complications of a minimally invasive transconjunctival sutureless vitreoretinal surgery for rhegmatogenous retinal detachments (RRD).

METHODS Non-randomized retrospective study. A total of 85 eyes of 85 patients with RRD were recruited from January 2009 to January 2011. 17 eyes (20%) had inferior breaks and 68 eyes (80%) had superior breaks. 55 eyes (65%) presented macula-off. All eyes did not have previous scleral buckling and all eyes underwent a complete 25 gauge pars plana vitrectomy. Laser retinopexy was done in all eyes. At the end of the surgery the appropriate tamponade was injected: perfluoropropane (C₃F₈) in 51 eyes (60%) and air in 34 eyes (40%). The main outcome measure was the anatomical reattachment rate. The secondary outcome measures were the improvement in visual acuity and recurrence rate of retinal detachment.

RESULTS The mean age of the patients was 56.9 years old (range 19-85). The mean follow-up duration was 19.6 months (range 12-36). The primary reattachment rate was

86% in the C₃F₈ tamponade group and 94% in the air tamponade group. The mean BCVA was 0.87 ± 0.62 logMAR in the C₃F₈ tamponade group and 0.86 ± 0.67 logMAR in the air tamponade group; at the last visit the BCVA was 0.17 ± 0.16 logMAR and 0.43 ± 0.36 logMAR respectively. In the C₃F₈ tamponade group 11 eyes (21.5%) had a recurrent retinal detachment: 7 eyes in the first postoperative month (13.7%) where C₃F₈ was used to reattach the retina; 4 eyes (7.8%) after 6 months had a recurrent retinal detachment with proliferative vitreoretinopathy (PVR) and PDMS was used as tamponade. In the air tamponade group 4 eyes (11.8%) had a recurrent retinal detachment: 2 eyes (5.9%) in the first postoperative month and C₃F₈ was used as tamponade; 2 eyes (5.9%) had a recurrent retinal detachment with PVR after 1 year from surgery and PDMS was used.

CONCLUSION The minimally invasive 25 gauge transconjunctival sutureless vitreoretinal surgery and C₃F₈ or air tamponade are efficacious and safe to treat primary RRD repair cases with both inferior and superior breaks. An accurate vitrectomy and C₃F₈ or air tamponade reduce the formation of PVR. In our series we found a lower rate of redetachment in the air tamponade group.

TAKE HOME MESSAGE The minimally invasive 25 gauge transconjunctival sutureless vitreoretinal surgery and C₃F₈ or air tamponade are efficacious and safe to treat primary rhegmatogenous retinal detachments.

11:54 AM

Epiretinal Membrane Formation and Cystoid Macular Edema Following Uncomplicated Primary Retinal Detachment Repair With Small-Gauge Pars Plana Vitrectomy



- Gayatri S. Reilly, MD
- Tanuj Banker
- Eric D. Weichel, MD

OBJECTIVE To evaluate the incidence of epiretinal membrane (ERM) and cystoid macular edema (CME) following small gauge pars plana vitrectomy (PPV) repair of primary rhegmatogenous retinal detachments (RD).

PURPOSE To evaluate the incidence of epiretinal membrane (ERM) formation and cystoid macular edema (CME) following small gauge pars plana vitrectomy (PPV) repair of primary rhegmatogenous retinal detachments (RD).

METHODS Consecutive interventional case series from 2002 to 2012 by one group of retina surgeons performing primary RD repair using either 23 or 25 gauge PPV instrumentation with or without scleral buckle (SB). Exclusion criteria included preoperative proliferative vitreoretinopathy, postoperative retinal re-detachment, pre-existing macular disease, previous PPV or SB, and documented follow-up of less than 3 months. Main outcome measures included rates of ERM/CME confirmed with either optical coherence tomography (OCT) or fluorescein angiography (FA). Secondary outcome measures included visual outcomes and risk factors for ERM and CME.

RESULTS 495 eyes with a mean age 56 years ± 15.6 years followed for a mean 404.8 ± 12.8 days. ERM developed in 150 eyes (30.3%) and CME developed in 73 eyes (14.75%). 101 eyes (20.4%) had a PPV/SB compared to 394 eyes (79.6%) with PPV. The mean preoperative visual acuity was 20/200 (logMAR 1.0 ± 1.1) improving to 20/40- (logMAR .33 $\pm .43$) postoperatively ($p < 0.001$). There was no statistically significant difference in postoperative visual acuity in PPV versus PPV/SB. ERM developed in 47/101 (47%) with a PPV/SB versus 103/394 (26%) with a PPV ($P = 0.002$). CME developed in 17/101 eyes (17%) with a PPV/SB compared to 56/394 eyes (14%) with a PPV ($P = 0.10$). There were 245 eyes (49.5%) that were phakic compared to 250 eyes (50.5%) that were pseudophakic. The mean final visual acuity was 20/40+ (logMAR 0.27 ± 0.42) in pseudophakic eyes compared to 20/50 (logMAR 0.39 ± 0.43) phakic eyes ($p = 0.002$). There was no statistically significant difference in rates of ERM and CME with regards to lens status.

CONCLUSION ERM and CME following uncomplicated small gauge RD repair are common postoperative findings. A significantly higher incidence of ERM formation was observed in cases of PPV/SB compared with PPV alone. Small gauge primary RD repair requires long term monitoring with OCT and FA to rule out postoperative ERM or CME.

TAKE HOME MESSAGE The incidence of ERM and CME are higher than previously reported following uncomplicated primary RD repair using small gauge vitrectomy.

12:04 PM

Retained Subretinal Perfluorocarbon Liquid in Sutureless 23-Gauge versus Sutured 20-Gauge Vitrectomy for Retinal Detachment Repair



- Sunir J. Garg, MD

OBJECTIVE To assess the incidence of subretinal perfluorocarbon liquid in sutureless 23 gauge vitrectomy compared to 20-gauge vitrectomy and to understand why this difference occurs.

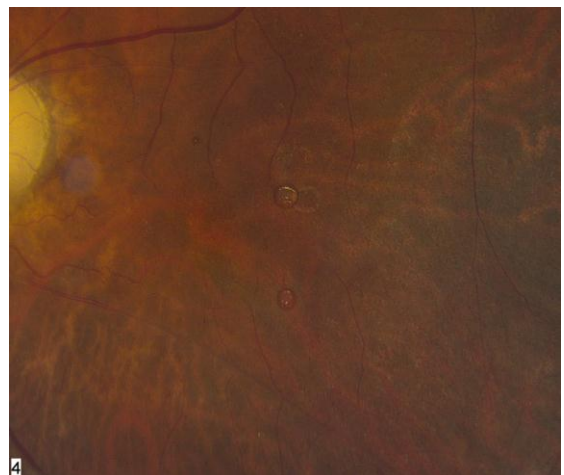
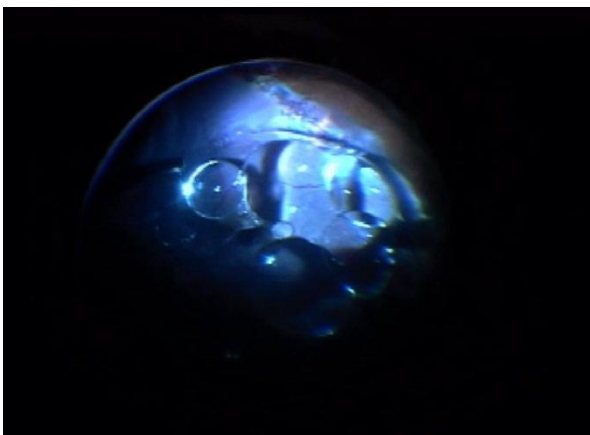
PURPOSE To assess the rate of retained subretinal perfluorocarbon liquid (PFCL) in patients undergoing rhegmatogenous retinal detachment (RRD) repair with sutureless 23-gauge vitrectomy versus sutured 20-gauge vitrectomy

METHODS A retrospective, consecutive, interventional, comparative case series. All patients with a diagnosis of RRD that underwent pars plana vitrectomy (PPV) with PFCL for RRD repair from 11/1/05 through 10/31/08 were included.

RESULTS A total of 234 RRD repairs were performed during the study period by one surgeon. Subretinal PFCL occurred in 4 of 176 eyes (2.3%) that underwent sutured 20-gauge PPV and in 6 of 58 eyes (10.3%) that underwent sutureless 23-gauge PPV for repair of retinal detachment ($p=0.0167$, Fisher exact test, two-tailed). Of the 176 eyes that underwent 20-gauge vitrectomy, there was 1 case of retained subretinal PFCL out of 113 eyes without PVR (0.9%) and 3 cases of retained subretinal PFCL out of 63 eyes that had membrane peel for PVR (with or without retinectomy) (4.8%, $p=0.1316$, Fisher exact test, two-tailed). Of the 58 eyes that underwent 23-gauge vitrectomy, there were 3 cases of retained subretinal PFCL out of 39 eyes without PVR (7.7%) and 3 cases of retained subretinal PFCL out of 19 eyes that had PVR (15.8%, $p=0.3822$, Fisher exact test, two-tailed). One eye in each group had visually significant subretinal PFCL that was removed with no improvement in vision.

CONCLUSION There is a significant 4.5-fold higher incidence of retained subretinal PFCL in patients undergoing RRD repair with sutureless 23-gauge versus sutured 20-gauge vitrectomy for RRD repair. Higher fluid flow through open 23-gauge cannulas disrupts PFCL surface tension resulting in small bubbles that can enter the subretinal space. Reduction of fluid flow may prevent this complication.

TAKE HOME MESSAGE High fluid flow through 23-gauge cannulas can disrupt the normally high PFCL surface tension. Reducing fluid flow, including through the use of valved cannulas, may prevent this complication.



12:08 PM

Comparative Study of Vitrectomy With and Without Internal Limiting Membrane Peeling for Rhegmatogenous Retinal Detachment

- Cyrus M. Shroff, MD
- Daraius N Shroff, MS FMRF FRCS
- Charu Gupta, MBBS, MS
- Gagan Bhatia, MBBS , DO , DNB
- Ajay Singh, MS
- Neelam Atri, MS

OBJECTIVE To study if ILM peeling has a beneficial effect on the anatomical and functional outcome of pars plana Vitrectomy for Rhegmatogenous Retinal Detachment

PURPOSE To compare the anatomical and functional outcome of Vitrectomy for macula off Rhegmatogenous retinal detachment in patients with and without peeling of the internal limiting membrane. The study aims to find out whether visual outcome, rate of macular pucker and anatomical attachment rates would differ in these two groups.

METHODS Retrospective non-randomized interventional case series. Patients with macula off retinal detachments of more than 15 days duration were included. 20 patients who had undergone brilliant blue assisted ILM peeling as part of their primary surgical procedure constituted the study group. 22 matched patients who did not undergo ILM peeling were included in the control group. Silicon oil was used as a tamponade in all patients. Exclusion criteria included recurrent detachments and post traumatic detachments. Pre- and post-operative best-corrected visual acuity and incidence of macular pucker were the primary outcome measures.

RESULTS Mean baseline age of patients, duration of detachment and pre operative vision were comparable in both groups. Pre and post operative logMAR best corrected visual

acuties (BCVA) at 6 weeks were 1.76 ± 0.61 and 0.93 ± 0.38 in the ILM peeling group ($p < .001$) respectively, and 1.71 ± 0.66 and 0.84 ± 0.58 in the Control group ($p < .001$). The difference in vision at 6 weeks between the groups was not statistically significant ($p = 0.56$) However a trend towards better improvement in vision in the ILM peeling group noted at 3 and 6 month follow up. Recurrent detachment was noted in two patients in the control group and in no patient in the ILM peeled group. One case in the Control group underwent ERM removal at the time of SOR, while this was not required in any case of the study group.

CONCLUSION ILM Peeling seems a safe procedure for relatively long standing RD cases . There was a lesser chance of pucker as well as recurrent RD in these patients. Both these could be related to the fact that ILM peeling ensures complete removal of the hyaloid from the posterior pole. The trend towards better visual acuity at 3 and 6 months confirms the long term safety and efficacy of this procedure.

TAKE HOME MESSAGE Peeling of the internal limiting membrane in cases of Retinal detachment is a challenging surgical manoeuvre procedure. However it shows definite benefits and does not compromise safety.

12:12 PM

Infero-Temporal Dialysis: A Genetic RRD in the Andes?

- Armando G. Sandoval, MD
- Sandra Larco, MD

OBJECTIVE This is an spontaneous RRD, commonly seen in young males of the Ecuadorian Andes, with a high incidence of bilaterality

PURPOSE To present the statistical analysis of etiology of RRD in the Ecuadorian Andes where ITD is one of the most common types and, to describe the clinical presentation of this particular type of retinal detachment that probably must have some genetic component concerning the population affected, the autoctonus inhabitants of this region .

METHODS Retrospective revision of 2 series of patients with RRD , that underwent scleral buckle surgery . Inclusion criteria : primary RRD with PVR \leq C1 with these etiologies : idiopathic , high myopia, trauma, aphakia, pseudophakia, and ITD. Exclusion criteria : RRD with PVR > C1, macular holes, GRT . The first group refers to 150 eyes of 131 patients operated during 17 years (1986-2002) , and the second has 32 eyes in 29 patients , operated in 6 years (2006-2011) . The procedure performed was : cryo + SB with 287 explant + SRF drainage in most of the cases and 240 band in cases with dialysis of 60 degrees or more.

RESULTS ITD is the most common RRD considering the total number of eyes. So in the first group of a total of 150 eyes operated , 51 eyes (34%) were ITD . In the second group, of 32 eyes , 11 were ITD that also belongs to 34 % . Considering the number of patients, the most common type of RRD is the idiopathic in both groups : 50 of 131 patients (38%) and 10 of 29 patients (34,4%). There is a high incidence of bilaterality 59 % (19 patients) in the first group and 37 % (3 patients) in the second. Considering the sex is more common in males, in ages between 15 and 35 years

CONCLUSION 1) ITD is a very common RRD in the Ecuadorian Andes .

2) There is a high incidence of bilaterality 3) It is more common in young males, between 15 and 35 years 4) The population mostly affected belongs to the autoctonus inhabitants of the region 5) Is there a genetic or environmental component that weakens the ora serrata ?

TAKE HOME MESSAGE This is an spontaneous RRD , probably genetic and with a high incidence of bilaterality, most common in young males.

