

**3:44 PM**

# Vitreoretinal Traction and Effectiveness of a Modified Vitrectomy Probe in Small-Gauge Vitrectomy: Experimental and Clinical Study

- Stanislao Rizzo, MD
- Michele Palla
- Gualtiero Fantoni, PhD
- Jonathan Ciampi
- Rodrigo Brant, MD, MBA
- Mark S. Humayun, MD, PhD
- Federica Genovesi Ebert, MD PhD

**OBJECTIVE** Modified cutters showed greater suction power with a better safety in comparison with the standard models as retinal traction increase caused by vacuum rise and proximity with the retina was reduced.

**PURPOSE** To evaluate the vitreous traction created by modified vitrectomy probe 23-, and 25-gauge(g) during vitrectomy. For this purpose standard and modified 25 and 23 g cutters performance was respectively compared in an experimental and in a clinical study. The modification has the aim to achieve a greater flow/minute and, at the same time, more stability and less tractions on the retina.

**METHODS** In the experiment the retinal layers of fresh porcine eyes were transfixated with a 0.15-mm steel wire and fixed to the load cell of a strain gauge. The cutter to be assessed was introduced by a micromanipulator at a 45° angle adjacent to the retina. Each pair of 25 and 23 g cutters (standard vs modified) was compared by analyzing the traction force at a distance of 3 and 5 mm from the retina with different vacuum and cut rates. In the clinical study we compared standard and modified 25 and 23 g cutters during vitreoretinal surgery (40 cases) by evaluating vitrectomy time, and incidence of complications. The study was completely independent and performed without any commercial support

**RESULTS** The analysis showed that with the standard probes , vitreoretinal traction increased by increasing the vacuum. Traction forces decreased by increasing the cut rates and increased at 3 mm compared with 5 mm. Both the modified probe showed that the increase in traction induced by the vacuum rise was less in respect to the standard ones. The reduction of traction forces achieved by increasing the cut rates was greater dealing with the modified cutters. In vitro all modified cutters showed a significant increase of the flow/min in comparison with the standard probes. Both in modified 23 and 25 gauge probes the aspiration time of 10 cc of BSS were about 50% less in comparison with standard ones. In vivo during the surgery vitrectomy times were respectively: with standard 25 g (10 cases) 781 seconds  $\pm$  200 vs modified 25.g (10 cases) 520  $\pm$ 180; with Standard 23 g (10 cases): 732 seconds  $\pm$  210 vs modified 23.g (10 cases) 473  $\pm$ 170. No intraoperative complications occurred in both groups.

**CONCLUSION** Effects of aspiration, distance from the retina, and cut rate are crucial factors in the amount of retinal traction created by vitreous cutters. Dealing with modified cutters, retinal traction increase caused by vacuum rise and proximity with the retina was reduced, therefore they showed greater suction power with a better safety in comparison with the standard models.

**TAKE HOME MESSAGE** Modified cutters showed greater suction power with a better safety in comparison with the standard models as retinal traction increase caused by vacuum rise and proximity with the retina was reduced.

**3:52 PM**

# Two-Year Results from the Argus® II Retinal Prosthesis System Clinical Trial

- Mark S. Humayun, MD, PhD
- G. Dagnelie, PhD
- J-S Sahel, MD
- Jacque L. Duncan, MD
- Robert J Greenberg, MD, PhD
- Lyndon da Cruz, MBBS, BA, MA, FRCOphth, PhD, FRACO
- E. Filley, PhD
- Dean Elliott, MD

**OBJECTIVE** To study the safety and probable benefit of the Argus® II Retinal Prosthesis System in an ongoing clinical trial.

**PURPOSE** The Argus II System is intended to provide electrical stimulation of the retina to induce visual perception in blind individuals. The System consists of an epiretinal prosthesis that is fully implanted on and in the eye, and an external unit worn by the user. The purpose of the clinical trial was to study the safety and probable benefit of the System in patients with retinitis pigmentosa.

**METHODS** Subjects had bare light perception or worse vision due to retinitis pigmentosa. All subjects were implanted with a Second Sight Argus II implant ([clinicaltrials.gov](http://clinicaltrials.gov/NCT00407602) NCT00407602; active, not recruiting). Visual function was evaluated by a grating visual acuity test as well as by assessing the ability to determine the direction of motion of a line and the location of a square on an LCD screen. Functional vision tests included in-clinic Orientation and Mobility (O&M) tests as well as the Functional Low-vision Observer-Rated Assessment (FLORA), which was performed by trained O&M and low-vision therapists in and around the subjects' homes.

**RESULTS** As of December 1, 2011, 30 subjects have been implanted at 10 centers (in the main study). Subjects have been implanted an average of  $3.2 \pm 0.9$  years (range of 2.3 – 4.5, excluding one subject explanted at 1.2 years). The initial rate of adverse events has

been further decreased by approximately 1.5x in the second half of subjects. Results on visual function tests with high-contrast stimuli showed that most subjects can locate an object, about half can detect the direction of motion, and about 1/4 have been able to distinguish grating orientation. To date, the best grating visual acuity measurement was 1.8 logMAR (20/1260). Functional vision O&M tests demonstrate that subjects are significantly better at performing visual tasks with the System ON vs. OFF even during long-term follow-up (i.e. >3years). As rated by independent trained observers in the FLORA, over half of the subjects demonstrated improvements in quality of life and/or functional vision when using the Argus II System.

**CONCLUSION** With over 95 cumulative patient-years of follow-up on 30 subjects, this is the largest study of a visual prosthesis to date. The results confirm and extend previous reports on the safety and ability of the Argus II prosthesis to provide visual function and functional vision over the long term. The Argus II Retinal Prosthesis System has received CE Mark and is now commercially available in Europe.

**TAKE HOME MESSAGE** The Argus II Retinal Prosthesis System clinical trial was shown to have an acceptable safety profile and to provide visual function & functional vision to subjects blind from Retinitis Pigmentosa

**4:04 PM**

# Combined Vitrectomy With Gas Tamponade and Posterior Glaucoma Tube Placement in the Management of Complicated Uveitic Glaucoma

- E. Mitchel Opremcak, MD
- Marena Patronas
- N. Douglas Baker, MD

**OBJECTIVE** To analyze the efficacy of pars plana vitrectomy and pars plana insertion of a glaucoma tube shunt with intravitreal gas tamponade in the management of advanced uveitic glaucoma.

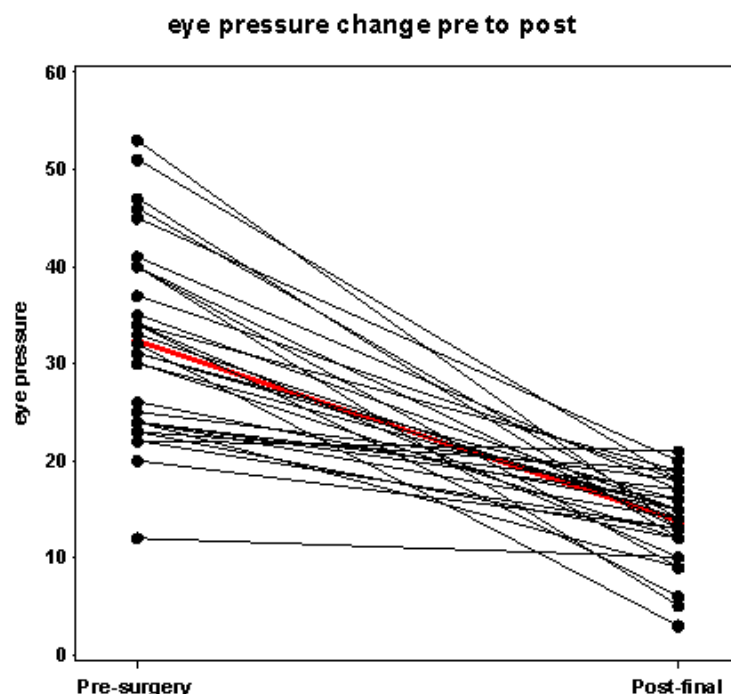
**PURPOSE** To analyze the efficacy of pars plana vitrectomy with gas tamponade and pars plana insertion of a glaucoma tube shunt in the management of advanced uveitic glaucoma. Outcome measures include reduction of intraocular pressure (IOP), post operative hypotony, number of glaucoma medications needed, visual acuities and control of uveitic recurrences following the combined surgical procedure.

**METHODS** This is a non-randomized, un-masked, retrospective chart review of patients with uncontrolled secondary glaucoma due to uveitis. Inclusion criteria were patients with progressive optic nerve glaucomatous change and intraocular pressures above 20. These patients, on maximum medical treatment had persistent uncontrolled IOP, and underwent combined pars plana vitrectomy and pars plana insertion of Baerveldt® Glaucoma Implant (Abott Medical Optics, Inc) by the same surgeons between 1994 and 2011. Pre and post operative IOP, number of glaucoma medications, visual acuity and uveitic recurrences were compared over the course of the patient follow up which ranged from 1-204 months.

**RESULTS** Included in the analysis were 32 eyes of 26 patients with uveitis and secondary glaucoma. The average age was 41.53 (range 9-81) of 11 male and 15 female patients. There were 12 right eyes and 20 left eyes with follow up ranging from 1 to 204 months (mean 33.4). The mean pre-operative IOP was 32.28 mmHg and the mean post operative IOP was 13.78 mmHg. There was a significant decrease of  $18.3 \pm 1.6$  mmHg between pre and post operative IOPs (p value  $<.0001$ ). The mean number of glaucoma medications used was 2.47 pre and 0.69 post operatively. There is a significant decrease of  $1.78 \pm 0.23$  medications required following surgical procedure (p value  $<.0001$ ). The visual acuities were either unchanged or better in 21/32 eyes (65%). Sixty percent (16/27) of eyes had no recurrence of ocular inflammation post operatively. Complications included: choroidals (1), tube occluded by vitreous which resolved with YAG vitreolysis or surgical revision (2), elevated IOP requiring cyclophotocoagulation (1).

**CONCLUSION** Combined vitrectomy, gas tamponade and pars plana placement of a glaucoma tube is a safe and effective method of lowering high IOP due to uveitic glaucoma. Patients required fewer glaucoma medications and had preserved or improved visual acuity in the majority of eyes. There were fewer recurrences of uveitis in these patients, both due to the posterior location of the tube and from vitrectomy.

**TAKE HOME MESSAGE** Uveitic glaucoma can be challenging and complicated to manage. We present a surgical technique designed to control pressures, minimize complications and treat uveitis in these challenging cases.



**4:12 PM**

## Rate of Sclerotomy Suturing in 23-Gauge and 25-Gauge Vitrectomy Surgery



- Kourous A. Rezaei, MD
- Renaud Duval, MD, FRCS(C)

**OBJECTIVE** To assess the frequency of suturing in small-gauge vitrectomy surgery.

**PURPOSE** To assess the rate of sclerotomy suturing in patients who undergo primary small-gauge vitrectomy surgery and to explore the factors that may influence it.

**METHODS** The operative report of patients who undergone 23-gauge or 25-gauge transconjunctival vitrectomies between 2008 and 2011 were reviewed in a multi-surgeon retina practice. Patients with history of previous retinal surgery, combination of vitrectomy and scleral buckling surgery, or intra-operative conversion of a sclerotomy to 20-gauge sclerotomy were excluded. Vitrectomies were divided into 2 types based on utilization of instrumentation and complexity. Type 1 vitrectomies used limited instrumentation (vitreous cutter and light pipe in all cases; soft tip cannula and/or endolaser probe in selected cases), while type 2 vitrectomies used more extensive instrumentation.

**RESULTS** A total of 329 eyes from 312 patients were included in this study. At least 1 sclerotomy was sutured in 189 eyes (57.4%): 1 sclerotomy was sutured in 51 eyes

(15.5%), 2 sclerotomies were sutured in 35 eyes (10.6%) and 3 sclerotomies were sutured in 98 eyes (29.8%). The superotemporal, superonasal and inferotemporal (infusion) sclerotomies were respectively sutured in 144 (43.8%), 140 (42.6%) and 131 (39.8%) of cases ( $p=0.574$ ). In the presence of air/gas tamponade 52.4% of the eyes required at least one sclerotomy sutured; however, in fluid filled eyes 63.9% of the eyes requires the suturing of at least one sclerotomy. This difference was statistically significant ( $p=0.0432$ ). Dividing the vitrectomies by complexity level yielded the following sclerotomy suturing rates when all 987 sclerotomies were analyzed individually: 299 out of 759 (39.4%) sclerotomies were sutured in type 1 vitrectomies vs 116 out of 228 (50.1%) for type 2 cases. This was statistically significant ( $p=0.0022$ ).

**CONCLUSION** The overall sclerotomy suturing rate in this study was 57.4%. Air/gas tamponade significantly reduced the suturing rate in small-gauge vitrectomies. While the location of the sclerotomy did not have a significant effect, more complex surgeries tended to be associated with a higher rate of sclerotomy suturing. Additional factors that may effect the rate of suturing is currently being studied.

**TAKE HOME MESSAGE** Small gauge sclerotomies may require suturing. Air/fluid exchange may reduce the rate of suturing. More complex vitrectomy cases have higher a likelihood of suturing.



**4:24 PM**

# Evaluation of Wound-Closure Morphology-of-Sclerotomy Sites Using Anterior Segment Spectral Domain Optical Coherence Tomography (AS OCT)



- Manish Nagpal, MD, FRCS (UK)

**OBJECTIVE** Healing characteristics of scleral ports following sutureless vitrectomy can be correlated in relation to wound construction

**PURPOSE** To evaluate the wound closure morphology of scleral ports in eyes undergoing sutureless vitrectomy

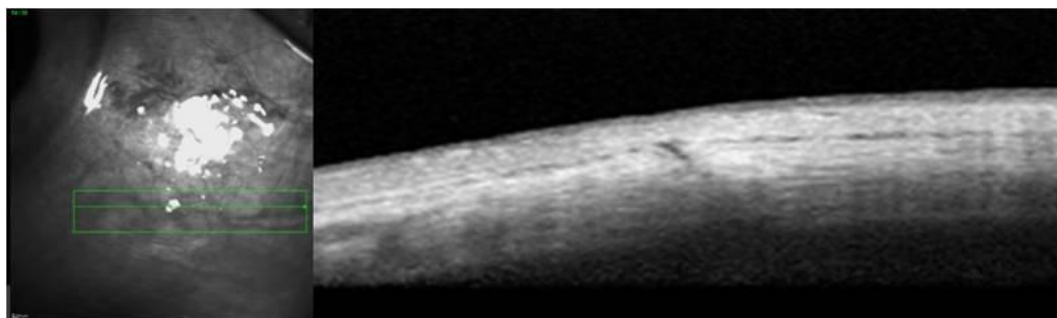
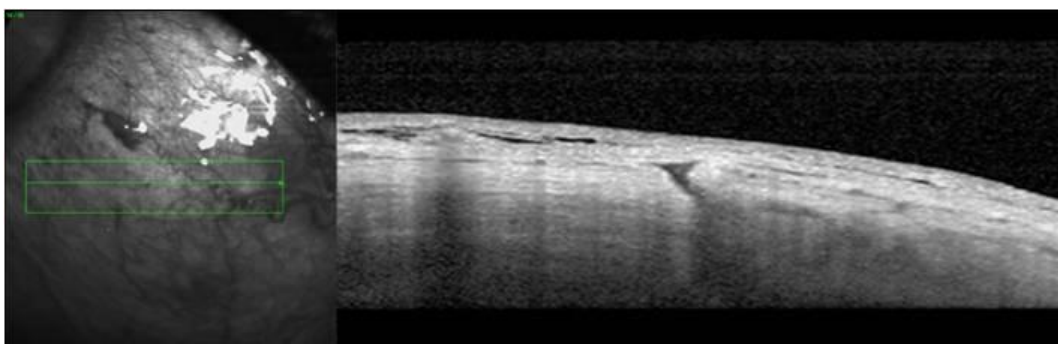
**METHODS** A prospective randomized study was conducted on 20 eyes which underwent sutureless vitrectomy were evaluated using Spectralis AS OCT on day 1, 15 and day 30. 10 eyes each belonged to 23 gauge (Group A) and 25 gauge (Group B). Scans were taken on the incision sites to note detailed wound size including its outer and inner dimensions. Group A cases were

further divided into group A1 and A2 on basis of the surgical time of <15 minutes and > 15 minutes duration respectively

**RESULTS** All cases on day 1 had uneventful postoperative recovery. The mean outer incision diameter on day one in group A was 236.6 microns and inner incision diameter was 146 microns. The corresponding values for group B were 118.6 microns and 90 microns respectively. A significant decrease ( $p < 0.0001$ ) in both the port sizes was observed in both groups on 15<sup>th</sup> and 30<sup>th</sup> day. The difference in the 2 groups with respect to decrease in the port sizes was also significant ( $p < 0.0001$ ) as group B showed more significant decrease in the port sizes on 15<sup>th</sup> and 30<sup>th</sup> day as compared to group A. The patients in whom the surgical duration was less than 15 minutes had relatively smaller incision as compared to those having surgical duration of more than 15 minutes on the 1<sup>st</sup> postoperative day though not statistically significant. ( $p > 0.05$ )

**CONCLUSION** In both groups the sclerotomy incisions showed good healing at one month duration. The 25 gauge sclerotomies showed better healing characteristics of wound morphology as compared to the 23 gauge sclerotomies. Longer surgical time has larger wound dimensions on day 1 though not statistically significant.

**TAKE HOME MESSAGE** Sclerotomy ports of sutureless surgery heal in 30 days duration and 25 gauge wounds have better wound characteristics as compared to 23 gauge



**4:28 PM**

# Wound Closure Evaluated With Optical Coherence Tomography After 25-Gauge Vitrectomy



- Makoto Inoue, MD
- Yuji Itoh
- Nozomi Watanabe
- Akito Hirakata, MD

**OBJECTIVE** A shorter wavelength OCT has a benefit to detect wound closure after 25-gauge vitrectomy and a longer wavelength OCT has a benefit to detect ciliary detachment.

**PURPOSE** To evaluate wound closure after 25-gauge microincision vitrectomy surgery (MIVS) with two different types of optical coherence tomography (OCT)

**METHODS** Intervention case series. MIVS was performed in 14 eyes. Transconjunctival incisions were created with 25-gauge instruments (Edgeplus, Alcon laboratories) with angled incision. The closure of the sclerotomies and presence of ciliary detachment at the temporal and nasal sclerotomies were examined with two different types of optical coherence tomography of OCT3000 (Carl Zeiss Meditec) scanned with 820 nm light and swept source OCT (SS-1000, CASIA, TOMEI Corp) scanned with 1300 nm light on

postoperative days 1, 3, and 7, and 30. A wound closure was defined as an absence of gap of scleral signal at the sclerotomy site.

**RESULTS** Postoperative hypotony ( $< 7\text{mmHg}$ ) was not detected in each eye. An unclosed incision of 28 sclerotomies was detected with OCT3000 in 19 sclerotomies (68%) on day 1, 16 sclerotomies (57%) on day 3, 6 sclerotomies (21%) on day 7, no sclerotomy (0%) on day 30. An unclosed incision of temporal sclerotomy was detected with SS-1000 in 8 sclerotomies (29%,  $P=0.003$ ) on day 1, 5 sclerotomies (18%,  $P=0.003$ ) on day 3, 2 sclerotomies (7%,  $P=0.126$ ) on day 7, no sclerotomy (0%,  $P=1.00$ ) on day 30. A ciliary detachment was not detected with OCT3000 in each time point, but it was detected with CASIA in 23 sclerotomies (93%,  $P<0.001$ ) on day 1, 18 sclerotomies (71%,  $P<0.001$ ) on day 3, 2 sclerotomies (7%,  $P=0.245$ ) on day 7, and no sclerotomy (0%,  $P=1.00$ ) with day 30.

**CONCLUSION** OCT was useful to evaluate wound structure after MIVS. OCT with a shorter wavelength light has a benefit to detect wound closure and OCT with a longer wavelength light has a benefit to detect ciliary detachment.

**TAKE HOME MESSAGE** A shorter wavelength OCT has a benefit to detect wound closure and a longer wavelength OCT has a benefit to detect ciliary detachment after 25-gauge transconjunctival vitrectomy.

**4:32 PM**

## Translational Development of a Subretinal Delivery System for Cell-Based Products



- Michael A. Samuel, MD
- Timothy M. Stout, MD
- Tom S. Chang, MD
- Marc D. de Smet, MDCM, PhD, FRCS
- Sicco Popma, PhD
- Allen C. Ho, MD
- Paul Williamson, MD
- Stan Conston, BS Physics
- Ron Yamamoto
- Terri Malone, MT(ASCP)

**OBJECTIVE** To report on the development of a microcatheter system for sub-retinal delivery of cell-based therapeutics

**PURPOSE** In a previous Phase 1 clinical trial, egress of cells through a retinotomy into the vitreal cavity may have facilitated traction retinal detachment. The purpose of this program was to develop a targeted surgical delivery system that obviated the need for a retinotomy and mitigated the risk of traction retinal detachments.

**METHODS** Exploratory surgical procedures using a retinotomy, various needles and fluorescein were performed in rabbits. Further exploratory surgical procedures using a microcatheter delivery system were performed in pigs and subsequently integrated into a Phase 1/2a clinical trial.

**RESULTS** In a pilot study using rabbits, regardless of needle gauge, administration of fluorescein through a previously created retinotomy resulted in reflux into the vitreal cavity. Use of a fiberoptic microcatheter allowed access to the peripheral subretinal

space, from which successful advancement of the catheter tip to the posterior retina occurred, with confirmation by examination of the fundus. This surgical procedure, as well as development of surgical instrumentation (wire-tipped microcannula, viscodissector and microretractor) was refined in pigs, with confirmation of delivery of cellular suspensions to the perimacular area. This surgical technique has been integrated into the ongoing clinical trial, CNTO2476MDG1002, for delivery of an allogeneic cell-based product. Further refinement in the clinical trial included enhancement of direct visualization of the procedure with intra-ocular endoscopy in order to mitigate surgical complications.

**CONCLUSION** Unmet medical needs will drive demand for innovative delivery solutions. Pre-clinical surgical models are important to refine surgical procedures and surgical instruments. An ongoing clinical trial of CNTO 2476 will show one approach using a cell therapy administered directly adjacent to the diseased posterior retina

**TAKE HOME MESSAGE** New technique for delivery of cell based product

**4:42 PM**

## Risk of Iatrogenic Retinal Tears in Small-Gauge Vitrectomy (PPV) Is Reduced by Initiating Surgery With Peripheral PPV Rather Than Traditional Core PPV



- Renaud Duval, MD, FRCS(C)
- John S. Pollack, MD
- Joanna M Hui, BS, BM
- Joseph M. Civantos, MD

**OBJECTIVE** To determine if the incidence of iatrogenic retinal tears during small-gauge PPV is related to whether the PPV procedure is initiated in the center of the vitreous cavity versus the periphery.

**PURPOSE** To compare the incidence of iatrogenic retinal tears during primary small-gauge vitrectomy surgery using two different vitrectomy techniques performed by two surgeons.

**METHODS** Retrospective chart review of 182 eyes that underwent primary small-gauge PPV for epiretinal membranes, macular holes or vitreous opacities by two surgeons. In 91 eyes, surgeon 1 initiated PPV with a central core vitrectomy, followed by induction of a posterior vitreous detachment (PVD) if necessary, and then removal of the peripheral vitreous. In the other 91 eyes, surgeon 2 initiated PPV with 360-degrees of peripheral vitrectomy followed by removal of any remaining central vitreous and induction of a PVD, if necessary. Patients were excluded if they have had a prior retinal surgery, a history of retinal tears or detachment, or less than two months of follow-up.

**RESULTS** 182 eyes of 175 patients were included in the analysis; 91 eyes for each technique. The average age was 70.5 in the core-first group and 71.1 in the periphery-first group. There was no statistical difference between the two groups in terms of gender, operated eye, pre-operative or final post-operative visual acuity, lens status, surgical gauge, use of ICG stain or indication for surgery. PVDs were induced surgically in 47.3% of the core-first group and 45.1% of the periphery-first group ( $p=0.8875$ ). Intra-operative retinal breaks occurred in 17.6% in the core-first group versus in 3.3% in the periphery-first group ( $p=0.0036$ ). Sub-group analysis revealed that this difference was statistically significant for retinal breaks occurring in patients for whom a PVD was induced surgically ( $p=0.0362$ ) but not in patients with pre-existing PVD ( $p=0.1042$ ). There was 1 intra-operative retinal detachment in each group and only 1 post-operative retinal detachment in the core-first group.

**CONCLUSION** Initiating primary small-gauge PPV with 360-degree peripheral vitrectomy, rather than traditional core vitrectomy, appears to be associated with a lower risk of iatrogenic retinal breaks in eyes that have not yet developed a PVD. This reduced risk is probably related to the minimization of antero-posterior peripheral retinal traction early in the course of the procedure.

**TAKE HOME MESSAGE** Initiating primary small-gauge PPV with 360-degree peripheral vitrectomy, rather than traditional core vitrectomy, might reduce the incidence of iatrogenic retinal breaks.



**4:46 PM**

# Novel Changes to Retinal Anatomy as Imaged by Intraoperative Optical Coherence Tomography During Repair of Rhegmatogenous Retinal Detachment



- Matthew P. Ohr, MD
- Justis P. Ehlers, MD
- Peter K. Kaiser, MD
- Sunil Srivastava, MD

**OBJECTIVE** To report the novel retinal ultrastructural changes occurring during the repair of rhegmatogenous retinal detachment (RRD) as identified by intraoperative optical coherence tomography (*iOCT*).

**PURPOSE** The architectural tissue dynamics during surgery of RRD repair are poorly understood. In this study, *iOCT* is utilized to evaluate and describe the *in vivo* anatomic alterations that occur during retinal detachment repair.

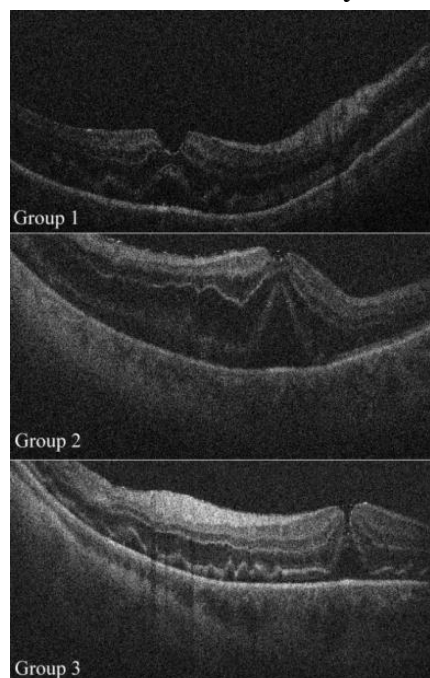
**METHODS** A consecutive case series identified eleven eyes that underwent pars plana vitrectomy (PPV) surgical repair for macula-involving RRD with *iOCT* imaging utilizing a surgical microscope-mounted spectral domain OCT system. Clinical variables were analyzed including duration, visual acuity, and procedure performed. Image acquisition was performed at various time points throughout the surgery [e.g., preincision,

following perfluoro-n-octane (PFO) instillation]Image characteristics were analyzed including for persistence of subclinical intraoperative subretinal fluid (SRF) and architectural changes associated with intraoperative maneuvers.

**RESULTS** Eleven eyes of 11 patients underwent iOCT during RRD repair. No cases were noted to have a macular hole (MH) prior to surgery. All patients underwent PPV. Ten of 11 eyes (91%) underwent a concurrent scleral buckle procedure. Significant alterations to the foveal architecture were detected with iOCT in 100% of cases. Three configurations were noted based on iOCT findings following instillation of PFO. Group 1 (4 of 11) eyes demonstrated a definitive area of subfoveal hyporeflectivity, group 2 (5 of 11) eyes had prominent subfoveal hyporeflectivity and significant foveal thinning with indeterminate MH, and group 3 (2 of 11) eyes demonstrated a definitive full-thickness MH undefined. None of these alterations were able to be visualized by the surgeon at the time of surgery and were only detectable utilizing the iOCT system. Persistent SRF was identified in 100% of eyes following PFO instillation. No eyes were noted to have a full-thickness MH in the early postoperative period.

**CONCLUSION** Microarchitectural changes occur during surgical repair of RRD, including significant alterations in foveal configuration, subclinical MH formation, and persistent SRF that are only able to be detected utilizing iOCT. Identifying these novel changes with iOCT may be important to better prognosticate visual/surgical outcomes and to improve our understanding of the pathogenesis of post-RRD MH.

**TAKE HOME MESSAGE** Intraoperative OCT provides a unique opportunity to observe *in vivo* changes to the retinal architecture that may ultimately lead to improved surgical outcomes.



**4:50 PM**

# A Mechanics-Based Model of a Detaching Retina

- Howard F. Fine, MD, MHSc
- Jonathan L. Prenner, MD
- Daniel B. Roth, MD
- William J Bottega, PhD

**OBJECTIVE** To advance the current technical view of retinal detachment by developing a rigorous mechanics based model of the phenomenon.

**PURPOSE** To advance the current technical view of retinal detachment and develop a rigorous mechanics based model of the process that will provide a basis for fundamental understanding of the phenomenon. Retinas with and without tears/holes are considered, and the contraction of the vitreous, as well as pressure due to sub-retinal fluid, are taken as the basic stimuli for the quasi-static process.

**METHODS** The mathematical model (Fig 1a) incorporates elements of structural and detachment mechanics (spherical shell theory and Griffith type detachment criterion) in an energy formulation. This yields the self-consistent energy release per unit detached area of retina as the "driver" of the detachment process, and formulae for critical stress radial deflection that provide a basis for measuring critical parameters (Fig 1b). It also gives the governing differential equations, which are then solved analytically in closed form for axisymmetric detachment. Numerical simulations based on these solutions are performed, yielding characteristic behavior.

**RESULTS** Threshold curves are presented for the detaching retina and reveal characteristic behavior. The model predicts that once detachment ensues it does so in an unstable manner. Numerical simulations utilizing measured physical properties available in the literature, including retina thickness to radius ratio of 0.008696 and tear angle of 0.05 radians, as well as Poisson's ratio of 0.3, reveal critical behavior and the factors that affect such behavior. "Dimpling" of the retina is predicted for

detachment angles<sup>3</sup>0.3 radians. The influence of altering material parameters such as fibril stiffness, Poisson's ratio, and thickness ratio, and tear size are presented. Under appropriate circumstances, the presence and size of a retinal tear can have a stabilizing effect on detachment propagation. A physical explanation as to why this is so is presented as well and follows directly from the mechanics of the phenomenon.

**CONCLUSION** A mathematical model to describe the mechanics of a detaching retina was devised. Exact analytical solutions with numerical simulations were performed. The model describes when a detachment will progress and predicts a "dimpling" phenomenon of the retina under specific circumstances. In some cases, retinal tears can have a stabilizing effect on detachment propagation.

**TAKE HOME MESSAGE** A rigorous mechanics based model of retinal detachment is developed to better understand fundamental processes and predict under what circumstances detachment will remain stable or progress.

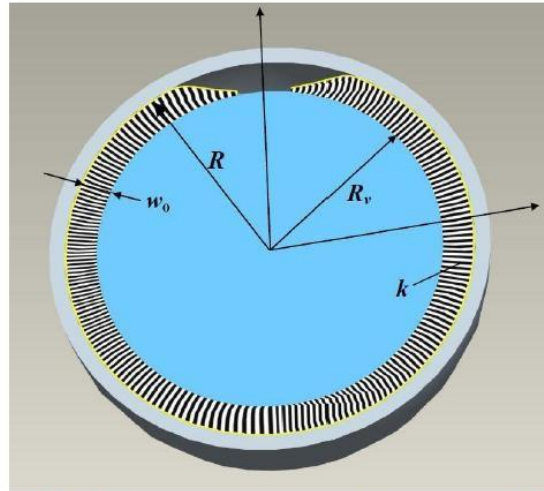


FIG. 1a: Model of detaching retina (with tear), contracted vitreous and extended fibrils

**Critical energy release per unit area for detachment progression:**

$$\mathcal{G}\{a\} = \left[ \frac{1}{2} M_{\varphi\varphi}^{(1)} \mathcal{Z}_{\varphi\varphi}^{(1)} + \frac{1}{2} N_{\varphi\varphi}^{(1)} \mathcal{E}_{\varphi\varphi}^{(1)} \right]_{\varphi=a} = 2\gamma$$

**Critical effective radial stress:**

$$\bar{\sigma}_{cr} = \sqrt{\frac{4\bar{\gamma}}{\bar{W}^{*n^2}(a)}}$$

**Critical crown-point deflection:**

$$\bar{\Delta}_{cr} \equiv \bar{w}(0)|_{\sigma=\sigma_{cr}} = \bar{W}^*(0) \sqrt{\frac{4\bar{\gamma}}{\bar{W}^{*n^2}(a)}}$$

FIG. 1b: Critical Parameters for Detachment Propagation

**4:54 PM**

# Unplanned Return to the Operating Room Following Vitreoretinal Surgery



- Jay M. Stewart, MD
- Marcela M Estrada
- Travis Porco, PhD, MPH

**OBJECTIVE** To understand the incidence and risk factors for unplanned reoperations in vitreoretinal surgery

**PURPOSE** Quality improvement efforts are gaining increasing importance in the current healthcare environment. Unplanned reoperation has been identified as an objective measure of surgical quality. We analyzed the quality of vitreoretinal surgery at a public hospital by determining the incidence of unplanned reoperation and by performing a case-control study to identify risk factors for this occurrence.

**METHODS** All vitreoretinal surgical procedures performed over a 12-year period at San Francisco General Hospital (SFGH) were identified through billing records and operating room logs. We then calculated the incidence of unplanned return to the operating room within 30 and 90 days following a vitreoretinal operation. For every case in which an unplanned return to surgery occurred, we selected four control

surgeries, matched on the basis of patient age and month of surgery. Risk factors for unanticipated return to the operating room were identified using a conditional logistical regression.

**RESULTS** Over the 12-year study period, 583 unique vitreoretinal surgeries were performed at SFGH. The incidence of unplanned return to the operating room within 30 days was 3.8% (n=22) and within 90 days was 9.6% (n=56). A total of 41 risk factors, including specific pre-operative diagnoses and intraoperative procedures, were analyzed in the regression. No variables were strongly associated with unplanned reoperation within 30 days, whereas the use of C<sub>3</sub>F<sub>8</sub> gas during surgery was strongly identified with return to the operating room within 90 days (P = 0.0004; adjusted P value = 0.018). Several other risk factors had weaker associations with this outcome.

**CONCLUSION** The incidence of unplanned reoperation following vitreoretinal surgery at SFGH was on par with reported rates in other surgical specialties. Identifying risk factors for this occurrence could help to improve patient outcomes following vitreoretinal surgery. Unplanned return to the operating room can be a useful indicator for evaluating quality of surgical care in ophthalmology.

**TAKE HOME MESSAGE** Measuring the incidence and risk factors for unplanned returns to the operating room can be a useful means of tracking surgical quality and identifying opportunities for improving outcomes.

**5:06 PM**

## Ophthalmicedge.org Version 2.0: Expansion and Analytics of a Free Educational Website

- Yale L. Fisher, MD
- David Y Kim, MD

**OBJECTIVE** Attendees will gain an understanding of the global impact of free web-based ophthalmic education that allows dynamic and interactive access to contributing experts.

**PURPOSE** *OphthalmicEdge.org* is a widely successful website founded by Dr. Yale Fisher in 2010 as a free educational resource for ophthalmic ultrasound. Re-released in 2012, version 2.0 includes new content beyond ultrasound with an esteemed bench of new contributing experts. We describe global usage analytics of this free tool that allows dynamic and interactive access to expert educational resources.

**METHODS** The website, originally focused on ophthalmic ultrasound, was expanded to include other imaging modalities as well as surgical techniques including content by Lawrence Yannuzzi and Robert Flower (indocyanine green angiography), Jay Duker (optical coherence tomography), Cynthia Kendall (ultrasound), Steve Charles (vitreoretinal surgery), Ed Ryan (scleral buckling), Harry Flynn (endophthalmitis), SriniVas Sadda (teaching cases), and Yale Fisher (endoscopy). A new Q&A section allows users to ask questions of the experts and post comments for other users. Users can customize notifications and filter content based on individual interest allowing for a dynamic approach to resource utilization.

**RESULTS** The website currently provides 21 lectures, 68 videos, 1 monograph, and 47 clinical examples in addition to access to 9 contributing experts who cover a variety of ophthalmic imaging and surgical techniques. Launch of *OphthalmicEdge.org* was accomplished in January 2010 with release of version 2.0 in February 2012. Internet-

based Google Analytics permit immediate evaluation of global penetration and usage for ongoing modifications and feedback. As of March 2012, there have been 33,672 visits and 143,588 page views from 17,617 unique users that come from 147 countries and 3,243 cities. Of the 10 cities with the most visits, the majority are from outside the United States. The website has been translated to 91 languages. The average time on the website is greater than 5 minutes. User feedback has been positive.

**CONCLUSION** *OphthalmicEdge.org* is a free educational website for ophthalmic clinicians. Web-based content allows for dynamic and interactive use. Internet-based survey permits evaluation of global penetration and usage analysis. Free access to ophthalmic education and recognized experts remains the goal.

**TAKE HOME MESSAGE** *OphthalmicEdge.org* is a free educational website allowing dynamic and interactive use and access to recognized experts. Analytics permit evaluation of global penetration and usage.



**5:10 PM**

## Determining Construct Validity of the Posterior Segment Anti-tremor, Bimanual, and Forceps Training Modules on the EYESi Virtual Reality Simulator



- Colin A. McCannel, MD

**OBJECTIVE** To assess how novice surgical learners perform advanced retinal surgical tasks on the EYESi Virtual Reality Simulator compared to experienced retina surgeons.

**PURPOSE** To assess the construct validity of the EYESi virtual reality surgical simulator.

**METHODS** Eye surgery naïve, including retina surgery, first year ophthalmology residents and experienced retina surgeons were assessed by each performing a predefined sequence of exercises on the EYESi virtual reality surgical simulator. These consisted of forceps training level 1, anti-tremor training level 3, performed with the dominant and non-dominant hand each, and bimanual training level 4 performed twice. Each exercise was repeated 5 times, and the built in scoring system of the surgical simulator was used. Resident performance was compared to retina surgeon performance, dominant was

compared to non-dominant hand use scores, and test-retest was compared to the bimanual task.

**RESULTS** 19 residents and 9 retina surgeons participated in the study. There were no significant differences between residents' and retina surgeons' scores for any of the modules tested, for both dominant and non-dominant hand as primary instrument hand. At the retest performance of bimanual testing, there was a strong trend ( $p=0.056$ ) that retina surgeons performed better than the residents and that retina surgeons performed better than on the first attempt ( $p=0.056$ ).

**CONCLUSION** Overall there was little difference in the performance of the retina surgeons compared to the novice surgeons. The greater improvement of the experienced retina surgeons on the repeat testing of the bimanual tasks suggests that initial unfamiliarity of the task environment (EYESi) may have limited the performance of all subjects.

**TAKE HOME MESSAGE** Learning to use the EYESi retina surgery simulator appears to have a learning curve for both novices and experienced surgeons. This learning curve may be masking construct validity in this trial.

**5:14 PM**

# Combined Scleral Tunnel Fixated Posterior Chamber Intraocular Lens and Pars Plana Vitrectomy in the Management of Posteriorly Dislocated Lenses

- Edmund Y.M. Wong, MBBS,MMed,FRCS

**OBJECTIVE** A novel technique for stable, scleral tunnel fixation of posterior chamber intraocular lens without glue, combined with pars plana vitrectomy, in the management of posteriorly dislocated lenses

**PURPOSE** To describe the indications, surgical technique, clinical outcomes, rate of recovery and complications of combined pars plana vitrectomy (PPV), removal of dislocated lens, and scleral tunnel fixation of posterior chamber intraocular lens (PCIOL) without glue in the management of posteriorly dislocated cataracts and intraocular lenses (IOL).

**METHODS** This retrospective study included consecutive patients with posteriorly dislocated cataracts or IOLs who consented to treatment with this novel technique. Exclusion criteria included cases with significant scleral pathology preventing stable fixation or other ocular pathology that precluded reasonable recovery of vision. Surgical method of combined surgery included 20- or 23-gauge PPV, lens removal, creation of partial-thickness scleral flaps and tunnels, insertion of 3-piece PCIOL, exteriorisation of haptics and fixation of haptics into scleral tunnels without glue. Visual acuity, intraocular pressure, cornea clarity, IOL centration and complications were recorded.

**RESULTS** Five patients satisfied the selection criteria; 4 were male. Median age was 60 years (range 54-78), follow-up was 4.5 months (range 1-6). Three of 5 patients (60%) had dislocated IOL and 2 had dislocated cataract with pre-existent ocular hypertension (OHT). Antecedent trauma occurred in 2 of 5 (40%). Median duration of surgery was 84

minutes (range 74-125). Within 5 weeks after surgery, best-corrected visual acuity was 20/30 or better in 4 of 5 (80%) eyes. Mild corneal edema resolved by 5 weeks in all cases. All PCIOLs were stable and well-centered at all times. IOP was elevated for only 1 day in 1 patient. The 2 patients with pre-existent OHT had normal IOP without therapy. Transient pupil capture of IOL lasting 10 minutes was noted in 1 patient. Thinning of the external wall of the scleral tunnel without overlying conjunctival defect was noted in 2 patients at the 3<sup>rd</sup> and 5<sup>th</sup> month. Cystoid macular edema occurred in 1 patient at 4 months, and resolved with topical nepafenac.

**CONCLUSION** Combined pars plana vitrectomy, removal of dislocated cataract or IOL, and scleral tunnel fixation of posterior chamber intraocular lens without glue was effective and relatively safe in patients with posteriorly dislocated cataracts and IOL. The combined procedure was relatively quick, allowed stable fixation, and good visual recovery within a reasonable time.

**TAKE HOME MESSAGE** A novel technique of scleral tunnel fixation of posterior chamber intraocular lens combined with pars plana vitrectomy promises long-term, stable lens fixation in posteriorly dislocated lenses.