

Improvement in Cystoid Macular Edema Secondary to Systemic Bevacizumab in a Patient With Coats Plus Syndrome

Journal of VitreoRetinal Diseases
2025, Vol. 9(1) 113–117
© The Author(s) 2024
Article reuse guidelines:
sagepub.com/journals-permissions
DOI: 10.1177/24741264241276601
journals.sagepub.com/home/jvrd



Saima Khan, BSA¹ , Cole A. Martin, MD, MPH¹ , Shannon Scarboro, BS¹,
Edward Wood, MD¹, and Clio A. Harper III, MD¹

Abstract

Purpose: To report a pediatric case of Coats plus syndrome that initially presented resembling familial exudative vitreoretinopathy (FEVR). **Methods:** A single case was analyzed. **Results:** A pediatric patient was referred at 2 years of age to the retina clinic for exotropia and decreased visual acuity in the right eye and was found to have a dense vitreous hemorrhage. She later developed persistent gastrointestinal bleeding requiring regular blood transfusions and intravenous bevacizumab. Treatment with systemic bevacizumab resolved the patient's cystoid macular edema (CME). Although her presentation and examination were initially suggestive of FEVR, genetic analysis revealed heterozygous biallelic mutations in the *STN1* gene, mutations that are known to be associated with Coats plus syndrome. **Conclusions:** Coats plus syndrome is a rare and life-threatening microangiopathy that affects the retina, central nervous system, and gastrointestinal system. The patient's resulting CME significantly improved with intravenous bevacizumab.

Keywords

Coats plus syndrome, familial exudative vitreoretinopathy, microangiopathy, retina, detachment, anti-VEGF, bevacizumab

Introduction

Coats plus syndrome, also known as cerebroretinal microangiopathy with calcifications and cysts, is a rare autosomal recessive disorder that typically affects the retina and the central nervous, gastrointestinal, skeletal, and integumentary systems.^{1,2} Dilated and tortuous retinal vessels, retinal neovascularization, retinal detachment (RD), and vision loss are common presentations.³ Other syndromic manifestations include seizure disorder, gastrointestinal bleeding, osteopenia, and early graying and loss of hair and nails.^{1,3} Coats plus syndrome is most often caused by a mutation in the *CTCI* gene but may also be associated with mutations in the *STN1* gene.

We report the case of a young female patient presenting with dense vitreous hemorrhage who was initially thought to have familial exudative vitreoretinopathy (FEVR) but ultimately was diagnosed with Coats plus syndrome. Her course was complicated by an RD, severe gastrointestinal bleeding, severe anemia, seizure disorder, and ascites. Treatment consisted of iron and packed red blood cell infusions, thalidomide, intravitreal (IVT) antivascular endothelial growth factor (anti-VEGF) injections, and intravenous bevacizumab, the last of which significantly reduced her bleeding and thus her dependence on blood transfusions. Intravenous bevacizumab also eliminated her dependence

on IVT anti-VEGF. She ultimately was admitted for distributive shock secondary to infection and died at the age of 12 years.

Case Report

A 2-year-old girl was referred to the retina clinic for exotropia and decreased visual acuity in the right eye with concerns for deprivation amblyopia. Her birth history was remarkable for intrauterine growth restriction, delivery at 35 weeks of gestation, and a 5-week stay in the neonatal intensive care unit. Although early examinations showed postnatal growth restriction and sparse graying hair, her ocular and family histories were unremarkable.

An initial examination under anesthesia (EUA) showed a dense vitreous hemorrhage, a falciform fold, and a posterior subcapsular cataract in the right eye. The left eye was normal at this time. Ultrasound of the right eye showed an attached retina,

¹ Austin Retina Associates, The University of Texas at Austin, Dell Medical School, Austin, TX, USA

Corresponding Author:

Clio Armitage Harper III, MD, Austin Retina Associates, Dell Medical School at the University of Texas at Austin, 801 W 38th St, Ste 200, Austin, TX 78705, USA.
Email: caharper@austinretina.com

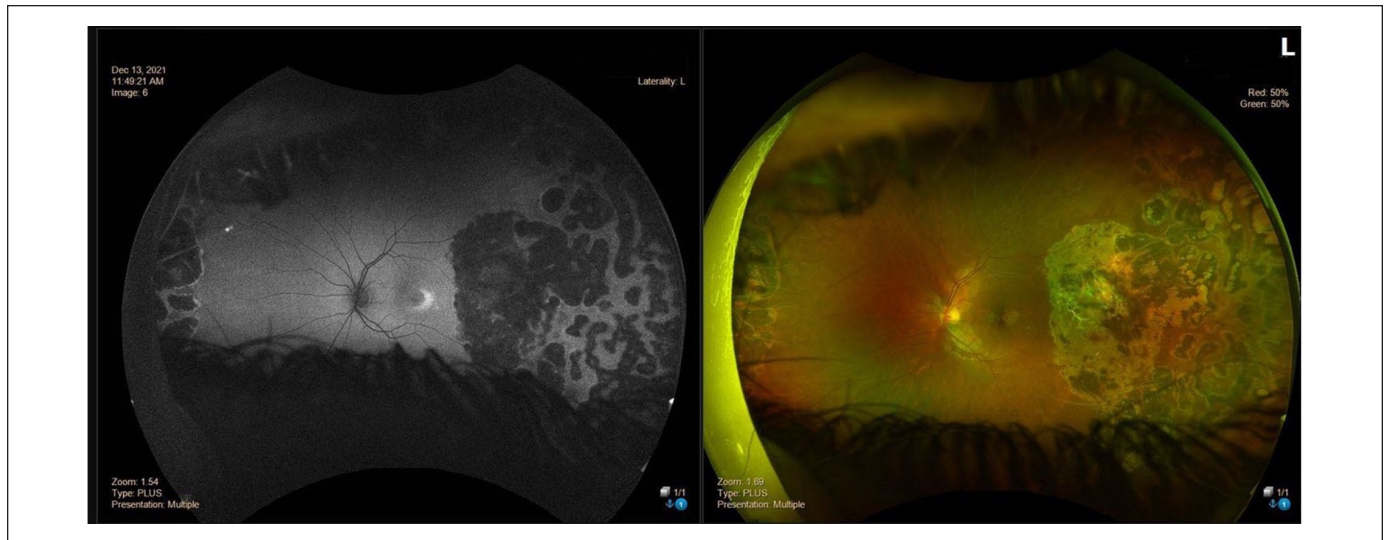


Figure 1. Fundus photograph of the left eye shows scarring from peripheral laser photocoagulation.

and computed tomography (CT) of the head showed intracranial calcifications and a 6.0 mm intraocular mass in the right eye, findings that are consistent with a dense vitreous hemorrhage. Accordingly, toxocariasis cultures were taken but were normal. No fluorescein angiography (FA) was performed at this time because it was not deemed necessary. The patient was sent to pediatric ophthalmology and continued care at the retina clinic, with evaluations approximately every 2 weeks until her next EUA.

One year later, the vitreous hemorrhage in the right eye had cleared, revealing the large falciform fold encompassing the right optic nerve and extending into the periphery; however, there was no evidence of active inflammation or hemorrhage. The patient's left eye was still normal at this time. FEVR was suspected because of the presence of the retinal fold and the patient's history of vitreous hemorrhage. An inherited retinal disease panel for thousands of retinal diseases was performed and was negative for 4 of the most common genetic culprits (*FZD4*, *LRP5*, *TSPAN12*, and *NDP*). FEVR could not be ruled out, however, because many other genes underlie the symptoms of this entity, for which testing is not typically done.⁴ Follow-up magnetic resonance imaging at this time confirmed stable enhancement of the basal ganglia, thalamus, and white matter, indicating intracranial calcifications and cysts. These findings were consistent with Coats plus syndrome.

At 5 years of age, the patient was found to have peripheral ischemia and edema in both eyes, with the left eye significantly worse than the right eye. Panretinal photocoagulation (PRP) was performed on both peripheral retinas (Figure 1). When the patient was 6 years old, an EUA found mild peripheral tractional RD in the right eye thought to be of ischemic etiology. Pars plana vitrectomy was performed with placement of a scleral buckle and oil tamponade. PRP was again performed in both eyes because of evidence of ischemia seen on FA.

The patient continued to have regular follow-up at least every 1 to 2 months, but further FA imaging was not performed until 8 years of age, when she developed cystoid macular edema in the left eye (Figure 2). FA showed vascular parafoveal lipid with peripheral avascularity and ischemia, and the patient was started on monthly IVT ranibizumab. She also received additional PRP to combat the production of VEGF by persistently ischemic retinas. The patient continued to have interim FA as needed.

By the age of 9 years, the patient developed neovascular glaucoma in the right eye with vascularization of the iris, an intraocular pressure of 40 mm Hg, and associated band keratopathy. Gonioscopy showed almost 360 degrees of posterior synechiae in the right eye and an angle open to the scleral spur greater than 360 degrees in the left eye. Pressure-lowering drops were started at this time. Progression of the posterior subcapsular cataract in the patient's right eye was noted and warranted cataract extraction and intraocular lens placement to facilitate further monitoring and treatment of the retinal disease.

For most of her early life, the patient's only significant symptoms were ocular. However, at the age of 10 years, she presented to the emergency department after a possible seizure event characterized by a 45-second episode of arm flailing and subsequent unresponsiveness for roughly 90 seconds. CT of the head showed no acute intracranial findings, with comments only pertaining to the previous findings consistent with Coats plus syndrome. A CT venogram found no dural sinus thrombosis, and an electroencephalogram suggested underlying structural cortical or white-matter dysfunction, explained by the patient's known intracranial calcifications.

Around this same time, the patient developed abdominal pain and significant blood in her stool and was found to be severely anemic, with hemoglobin levels as low as 1.9 g/dL.

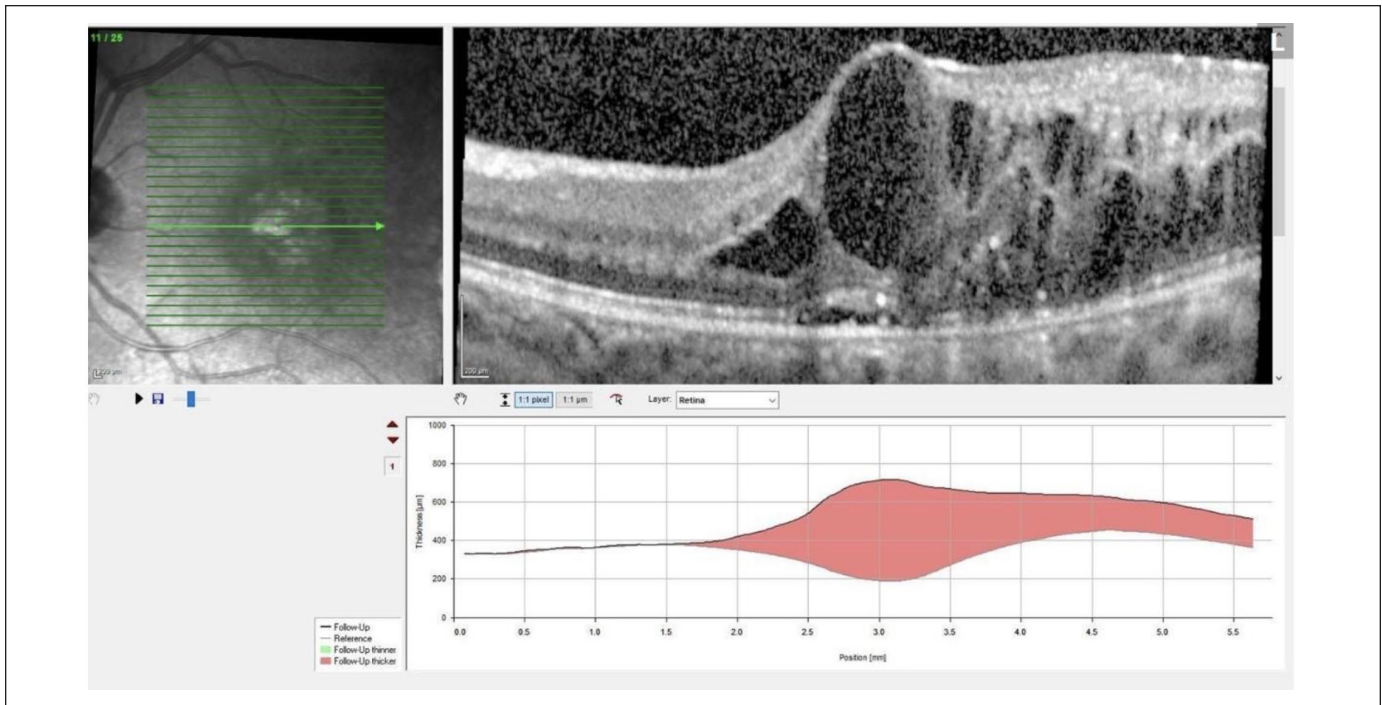


Figure 2. Edema of the left eye before systemic bevacizumab is seen on an image taken on July 22, 2020.

Transfusions of packed red blood cells every other week were initiated as well as regular iron infusions to maintain safe hemoglobin levels. An endoscopy showed ectatic vessels in the small bowel with marked bleeding and significant blood in the second, third, and fourth portions of the duodenum. A biopsy of the bowel and magnetic resonance angiography of the abdomen and pelvis were normal. A colonoscopy and bone marrow aspiration at this time were also normal. A liver ultrasound showed stage II to III fibrosis and normal blood flow on Doppler venography.

The patient continued to bleed profusely into her gastrointestinal tract, and at age 11 years she was started on thalidomide, a medication often used to control bleeding from angiodysplastic gastrointestinal lesions, to no avail.⁵ Ultimately, she began receiving intravenous bevacizumab, another measure shown to be effective in several patients with severe bleeding secondary to angioectasias of the digestive tract.⁶ This intervention was effective and resulted in noticeably less blood in her stools, less abdominal pain, and a decreased frequency with which she required blood transfusions. After starting bevacizumab therapy, she no longer required monthly IVT anti-VEGF injections.

Because of the patient's persistent blood loss without a clear etiology and because clarity could provide clinical guidance with regard to treatment and surveillance decision-making, additional genetic testing for mutations related to telomere loss was performed. The patient was found to be negative for mutations in *CTCI*, which is the most commonly implicated gene in Coats plus syndrome/cerebroretinal microangiopathy with calcifications and cysts.⁷ However, she was positive for heterozygous biallelic mutations in *STN1*, which has also been associated with the occurrence of Coats plus syndrome.⁸

Over the next 18 months, the patient was diagnosed with several separate episodes of spontaneous bacterial peritonitis, enterocolitis, and gastritis. At the age of 12 years, she was admitted for distributive shock secondary to *Escherichia coli* peritonitis, methicillin-sensitive *Staphylococcus aureus* pneumonia, acute COVID-19 infection, and hypovolemic shock from persistent gastrointestinal blood loss. She was also found to have nonhemorrhagic strokes in the distributions of the right middle cerebral artery and right anterior communicating artery.

Despite broad-spectrum antibiotics and high-dose vasoactive medications, the patient had worsening hemodynamic instability, oxygenation, and ventilation with mixed respiratory acidosis and lactic acidosis. In the setting of multisystem organ failure, her condition was deemed to be irreversible and terminal. A discussion with the patient's family led to the decision to allow the patient to die peacefully.

Conclusions

Our patient initially presented with a vitreous hemorrhage. Signs of FEVR include avascularity of the peripheral retina, dragged retinal vessels and macula, falciform retinal folds, neovascularization, subretinal exudates, and RD.⁹ Each of these signs was seen on physical examination throughout the patient's history; however, no genetic evidence of FEVR was found. Instead, genetic analysis showed heterozygous biallelic mutations in *STN1*.

Coats plus syndrome is mediated primarily by dysfunction of the *CTCI-STN1-TEN1* complex, which is responsible for the downregulation and upregulation of telomere elongation and is implicated in human telomeropathies such as Coats plus syndrome.¹⁰ Extraocular manifestations of such a telomeropathy

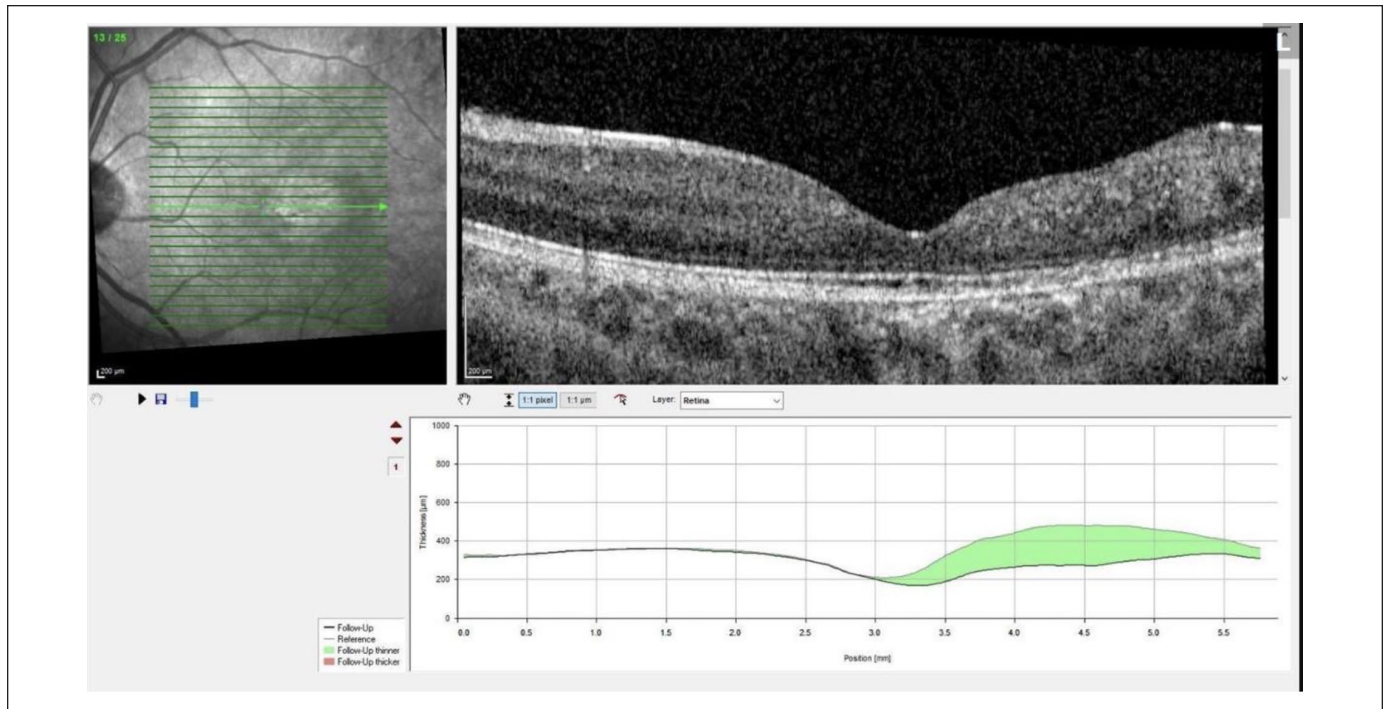


Figure 3. Edema of the left eye after systemic bevacizumab is seen on an image taken on December 13, 2021.

include intrauterine growth retardation, developmental delay, cerebral calcifications and cysts, portal hypertension, gastrointestinal blood loss, skeletal anomalies, and integumentary dysfunction that includes early graying and brittleness of the hair.^{1,2,3,11} Our patient had nearly all these symptoms; thus, her diagnosis of Coats plus syndrome, confirmed by genetic analysis, although rare, was unsurprising.

Of note, the use of intravenous bevacizumab in this patient's case, while targeted at the incessant gastrointestinal bleeding, proved useful in treating the retinal leakage and edema (Figures 2 and 3). Before starting intravenous bevacizumab, our patient was receiving IVT aflibercept on a monthly basis. After the initiation of bevacizumab, IVT injections were no longer required. Of course, this is an expected outcome because the use of bevacizumab to treat choroidal neovascularization was first observed in the early 21st century in cancer patients whose comorbid age-related macular degeneration (AMD) improved after systemic anti-VEGF administration. However, for many years there were limited data regarding the improvement of neovascularization secondary to diseases other than AMD after systemic bevacizumab. Reports of such improvement did not include patients with Coats plus syndrome.¹² More recently, 1 other case of systemic bevacizumab to treat neovascularization in Coats plus syndrome was reported, although data remain limited.¹³

In young patients with a clinical presentation resembling FEVR but with unclear genetic analysis results, Coats plus syndrome should be included in the differential diagnosis. Providers should also consider the impact and potential benefit of systemic anti-VEGF treatment on their own treatment plan when it is being administered by another provider—in this patient's

case by a gastroenterologist for intractable digestive tract bleeding related to Coats plus syndrome.

There continues to be limited research on Coats plus syndrome, although the consequences, including loss of vision, neurologic deficit, and gastrointestinal bleeding, are potentially devastating. This case report adds insight into the presentation and treatment of this rare syndrome.

Authors' Note

Presented at the conference of the Third Coast Retina Club, April 22, 2023, Austin, TX, USA.

Ethical Approval

This case report was conducted in accordance with the Declaration of Helsinki. The collection and evaluation of all protected patient health information were performed in a US Health Insurance Portability and Accountability Act-compliant manner.

Statement of Informed Consent

Informed consent, including permission for publication of all photographs and images included herein, was obtained before the procedure was performed.

Declaration of Conflicting Interests

The authors declared no potential conflicts of interest with respect to the research, authorship, and/or publication of the article.

Funding

The authors received no financial support for the research, authorship, and/or publication of this article.

ORCID iDs

Saima Khan  <https://orcid.org/0000-0002-5820-7536>

Cole A. Martin  <https://orcid.org/0000-0001-6025-4342>

References

1. Bozkurt S, Usta AM, Urganci N, Kalay NG, Kose G, Ozmen E. Coats plus syndrome: a rare cause of severe gastrointestinal tract bleeding in children – a case report. *BMC Pediatr*. 2022;22(1):119. doi:10.1186/s12887-022-03140-5
2. Maia C, Batista M, Palavra F, Pinto J. Coats-plus syndrome: when imaging leads to genetic diagnosis. *BMJ Case Rep*. 2022;15(5):1. doi:10.1136/bcr-2022-249702
3. Agrawal KU, Kalafatis NE, Shields CL. Coats plus syndrome with new observation of drusenoid retinal pigment epithelial detachments in a teenager. *Am J Ophthalmol Case Rep*. 2022;28:101713. doi:10.1016/j.ajoc.2022.101713
4. Wood EH, Drenser KA, Capone A. Diagnosis and management of familial exudative vitreoretinopathy: a lifelong, progressive, and often asymmetric disease. *JAMA Ophthalmol*. 2019;137(9):1059-1060. doi:10.1001/jamaophthalmol.2019.1484
5. de Koning DB, Drenth JPH, Friederich P, Nagengast FM. Thalidomide for the treatment of recurrent gastrointestinal blood loss due to intestinal angiodysplasias. *Ned Tijdschr Geneesk*. 2006;150(36):1994-1997. <https://www.ncbi.nlm.nih.gov/pubmed/17002190>
6. Masood M, Coles M, Sifuentes H. Management of refractory gastrointestinal bleeding in hereditary hemorrhagic telangiectasia with bevacizumab. *Case Rep Gastrointest Med*. 2021;2021:2242178. doi:10.1155/2021/2242178
7. Anderson BH, Kasher PR, Mayer J, et al. Mutations in *CTCI*, encoding conserved telomere maintenance component 1, cause Coats plus. *Nat Genet*. 2012;44(3):338-342. doi:10.1038/ng.1084
8. Simon AJ, Lev A, Zhang Y, et al. Mutations in *STN1* cause Coats plus syndrome and are associated with genomic and telomere defects. *J Exp Med*. 2016;213(8):1429-1440. doi:10.1084/jem.20151618
9. Tian T, Chen C, Zhang X, Zhang Q, Zhao P. Clinical and genetic features of familial exudative vitreoretinopathy with only-unilateral abnormalities in a Chinese cohort. *JAMA Ophthalmol*. 2019;137(9):1054-1058. doi:10.1001/jamaophthalmol.2019.1493
10. Chen LY, Majerská J, Lingner J. Molecular basis of telomere syndrome caused by *CTCI* mutations. *Genes Dev*. 2013;27(19):2099-2108. doi:10.1101/gad.222893.113
11. Collin A, Lecler A. Coats plus syndrome. *JAMA Neurol*. 2019;76(4):501. doi:10.1001/jamaneurol.2018.4610
12. Nguyen QD, Shah SM, Hafiz G, et al. Intravenous bevacizumab causes regression of choroidal neovascularization secondary to diseases other than age-related macular degeneration. *Am J Ophthalmol*. 2008;145(2):257-266. doi:10.1016/j.ajo.2007.09.025
13. Boulanger E, Barjol A, Chapron T. Efficacy of systemic bevacizumab on Coats plus syndrome. *Ophthalmol Retina*. 2022;6(10):905. doi:10.1016/j.oret.2022.05.029