

8:38 AM

Antibacterial Properties of 2 Percent Lidocaine on Staphylococcus and Streptococcus Species and Reduced Rate of Post-injection Endophthalmitis



- Stephen J. Kim, MD
- G. Baker Hubbard, MD
- Amy Chomsky, MD
- Aaron Tustin
- Jinsong Sheng, MD

OBJECTIVE To determine whether application of subconjunctival 2% lidocaine for anesthesia reduces rates of endophthalmitis after intravitreal injection.

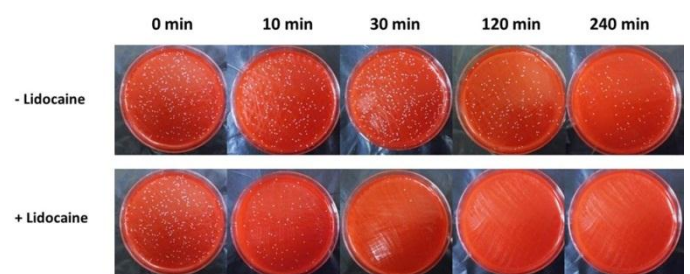
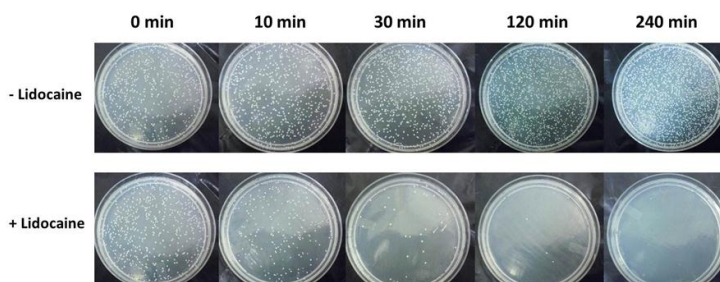
PURPOSE We performed *in vitro* experiments to confirm the antibacterial properties of 2% lidocaine against causative organisms of endophthalmitis and performed a retrospective chart review to determine the rate of intravitreal injection-related endophthalmitis with or without the pre-application of subconjunctival 2% lidocaine.

METHODS Isolates of *Staphylococcus aureus*, *Staphylococcus epidermidis*, and *Streptococcus viridans* from patients with endophthalmitis were incubated with either 2% lidocaine/0.1% methylparaben or equal volume distilled water (control). Aliquots (100 µl) were plated at 0, 10, 30, 120, and 240 minutes and colonies were counted after 24 hours. Number of intravitreal injections was determined by procedure code and endophthalmitis cases were identified using ICD-9 codes. Endophthalmitis cases were only included if they occurred within 7 days after an injection and either had a positive culture or hypopyon.

RESULTS *In vitro*, 2% lidocaine/0.1% methylparaben demonstrated rapid bactericidal effects against *Staphylococcus aureus*, *Staphylococcus epidermidis*, and *Streptococcus viridans*. After 10 minutes of exposure, there was approximately a 90% ($P < 0.01$), 95% ($P < 0.001$), and 92% ($P < 0.001$) reduction in colony forming units (CFU) when compared to time 0 for *S. aureus*, *S. epidermidis*, and *S. viridans* respectively. Complete elimination of CFU occurred at subsequent time points for each organism in contrast to logarithmic increase for control plates. There were a total of 8 cases (7 culture positive; 1 hypopyon) of post-injection endophthalmitis out of 7969 (0.1%) intravitreal injections performed without the use of subconjunctival lidocaine. In contrast, there were 0 cases out of 7224 injections performed with subconjunctival lidocaine ($P = 0.02$).

CONCLUSION Application of subconjunctival 2% lidocaine for anesthesia may reduce the incidence of post-injection endophthalmitis.

TAKE HOME MESSAGE Application of subconjunctival 2% lidocaine for anesthesia may reduce the incidence of post-injection endophthalmitis.



8:54 AM

Laboratory Investigation of an Endophthalmitis Outbreak Caused by Streptococcus mitis/oralis Group after Intravitreal Injection of Bevacizumab



- Harry W. Flynn, MD
- Paulo J.M Bispo
- Martha Diaz, MT
- Edith Perez, Bachelor Degree in Laboratory Science
- Roger A Goldberg, MD, MBA
- Darlene Miller, DHSc

OBJECTIVE

To report the laboratory profiles of alpha-hemolytic streptococci recovered from patients who developed acute onset endophthalmitis after injection of Bevacizumab

PURPOSE

To characterize the phenotypic and genotypic profiles of alpha-hemolytic streptococci recovered from patients who developed acute-onset endophthalmitis after injection of bevacizumab.

METHODS

Conventional and molecular techniques were used to identify and characterize alpha-hemolytic *Streptococci* isolates from intraocular fluids (vitreous and/or aqueous) of 9 patients (n=14 isolates) and from unused bevacizumab syringes within the same lot (n= 4 isolates) utilizing biochemical tests (Vitek 2), antimicrobial susceptibility testing (E-test) and PCR plus sequencing of the *groEL* gene.

RESULTS

Conventional biochemical tests confirmed the isolates from intraocular fluids as belonging to the *Streptococcus mitis/oralis* group. All isolates were susceptible to moxifloxacin and vancomycin, but demonstrated intermediate resistance to penicillin. DNA sequence analysis permitted final species identification for isolates as *S. oralis* (2 isolates) and placed all the other isolates within the *S. mitis* group.

CONCLUSION

Both conventional (phenotypic) and molecular (genotypic) methods identified the isolates from patients and from unused bevacizumab syringes as belonging to the *S. mitis/oralis* group. Both techniques implicate the repackaged bevacizumab syringes as the common source vehicle of this outbreak.

TAKE HOME MESSAGE

In the recent outbreak of endophthalmitis occurring after bevacizumab, conventional and molecular methods identified the isolates as belonging to the *S. mitis/oralis* group.

9:02 AM

Outbreak of Fusarium Endophthalmitis Following Brilliant Blue G (BBG) Dye-Assisted Vitrectomy Procedures



- Michael J. Davis, MD
- Kristie L. Lin, MD
- Tom S. Chang, MD
- Michael A. Samuel, MD
- Rizwan A. Bhatti, MD
- Pravin U. Dugel, MD
- Steven M. Friedlander, MD
- Anthony J. Culotta, MD
- Vincent S. Hau, MD, PhD
- Ivan G. Castillo Salazar, MD
- Nishita S Patel, MD
- Sharon M Theodore, MD
- Ragui W Sedeek, MD
- Kevin K. Suk, MD

OBJECTIVE To present diagnostic and treatment information for cases of fungal endophthalmitis following Brilliant Blue G dye-assisted vitrectomy surgery

PURPOSE To review the presentation of fungal endophthalmitis and the diagnostic dilemma it presents to the clinician, and to review the treatment regimen required to treat these resilient organisms

METHODS This is a case review of at least 13 patients from two locations in the United States afflicted with probable fungal endophthalmitis following vitrectomy surgery with BBG dye. Patient symptomatology and presentation, treatment regimens (both surgical and medical), and responses to therapy will be reviewed. Co-morbidity factors that may affect patient outcomes will also be examined.

RESULTS There are 13 patients from 3 Retina practices at 2 locations (further possible cases are pending) affected by a recent outbreak of *Fusarium* endophthalmitis. All patients underwent vitrectomy with BBG dye. The dye was compounded from a single compounding pharmacy and *Fusarium* was cultured from unused vials returned to the pharmacy. All patients presented with an insidious inflammation weeks after the procedure and were treated initially as both noninfectious and infectious endophthalmitis, as the presentation is not typical or consistent between cases. Most patients required further vitrectomy surgery, removal of the IOL and/or lensectomy, multiple intravitreal injections, as well as systemic antifungal medications. Further data discussing outcomes will be available upon presentation.

CONCLUSION Fungal endophthalmitis presents as both a diagnostic and treatment dilemma. Retina surgeons should have this diagnosis in their differential diagnosis when a patient presents with inflammation weeks to months after surgery. The presentation is not always typical of infectious endophthalmitis and the treatment regimen is both arduous and lengthy.

TAKE HOME MESSAGE Fungal endophthalmitis is difficult to diagnose and treat in a postoperative setting and should be in the differential diagnosis of atypical postoperative inflammation.

9:10 AM

Endophthalmitis Following Vitrectomy: A Prospective and Nationwide UK Study

- Somdutt Prasad, MS, FRCSEd, FRCOphth, FACS
- Jonathan C Park, MBChb BSc (Hons)
- Ramasamy Balasubramanian, MS, FRCOphth
- Roland Ling, BM BCh, FRCOphth

OBJECTIVE To gain greater understanding of endophthalmitis following vitrectomy.

PURPOSE To establish the incidence, clinical features, risk factors, management and outcome of acute, presumed infectious endophthalmitis following vitrectomy surgery in the UK.

METHODS This is a two-year (May 2010 to May 2012), nationwide, prospective, observational and case-control study of endophthalmitis within 6 weeks of pars plana vitrectomy (PPV), in association with BOSU (British Ophthalmic Surveillance Unit). Endophthalmitis case information was obtained via a questionnaire sent to Ophthalmologist who reported the case to BOSU. Information relating to controls (patients with PPV but no endophthalmitis) was compared to cases to identify risk factors for endophthalmitis. Controls were prospectively and randomly selected. To estimate the true incidence rather than simply the reported incidence, validation centres were used to establish under-reporting.

RESULTS With 22 months of prospective surveillance completed, 25 cases of endophthalmitis have been recruited (note at time of abstract two further months of surveillance is pending so more cases are anticipated). 75% were culture positive. Approximately 23,764 PPV's are performed per year in the UK, so this gives the annual incidence to be approximately 1 in 1742 (not yet corrected for under-reporting with validation centres). 270 controls were prospectively and randomly recruited. 70% of these were 20G and 30% were 23/25G. 55% of PPV's were for retinal detachment, 18% for macular hole, 16% epri-retinal membrane and 7% diabetic retinopathy. By

comparing cases with controls, risks for endophthalmitis have been identified which includes the indication for PPV being diabetic vitreous haemorrhage (relative risk 8.75, $p = 0.001$). Relative to 20G surgery, 23/25G surgery was associated with a relative risk of 3.2, but this currently does not reach statistical significance ($p = 0.09$).

CONCLUSION This study is the largest prospective study to investigate endophthalmitis following vitrectomy. It highlights that diabetic vitreous haemorrhage is a major risk factor for endophthalmitis. There is a trend for 23/25G surgery relative to 20G surgery to increase the risk of endophthalmitis but this is not currently statistically significant.

TAKE HOME MESSAGE There is a small but significant incidence of endophthalmitis following pars-plana vitrectomy. Vitrectomy for diabetic eye disease and small gauge sutureless vitrectomy may increase this risk.

9:26 AM

Microbiologic Analysis in Office-Based Microincision Vitrectomy Surgery



- Flavio A. Rezende, MD, PhD
- Cynthia Xin-ya Qian, MD
- Przemyslaw Sapieha, PhD

OBJECTIVE To determine the microbiological profile of patients undergoing office-based micro-incision vitrectomy surgery (MIVS).

PURPOSE To perform a microbiologic analysis of the vitreous during office-based MIVS and to assess whether the bacteria detected correlated with patient's ocular conjunctival flora.

METHODS This was a prospective nonrandomized case series of patients undergoing office-based MIVS, anti-VEGF, and dexamethasone intravitreal injections (triple therapy) for the treatment of wet age-related macular degeneration (AMD) and diabetic macular edema (DME). All patients were operated at a small procedure room in an ambulatory clinic of the Department of Ophthalmology, University of Montreal, Quebec, Canada. Conjunctival samples were done before placing the sclerotomies. The MIVS was

done with a 23-gauge retractable vitrector, a 27-gauge infusion line, and a 29-gauge chandelier. Undiluted and diluted vitreous were collected for aerobic, anaerobic and fungal cultures.

RESULTS Thirty-four patients (34 eyes) were recruited and completed 6 months follow-up. Twenty-five had wet AMD and 9 had DME. There were 10 men and 24 women, mean age of 69 years. Fifteen patients (44%) had culture positive conjunctival flora. Twenty-three bacterial colonies were tabulated in total from the conjunctival swabs, divided into 9 types of strains. All bacteria detected were gram-positive bacteria (100%), most commonly: corynebacterium colonies in 6 (26%); staphylococcus epidermitis in 5 (22%); and coagulase-negative staphylococci in 4 samples (17%). Only 1/15 patients had ≥ 3 strains isolated, 6/15 patients had 2 strains and 6/15 patients had 1 strain identified on the conjunctival swab. All undiluted vitreous samples were negative for bacteria. One diluted vitreous sample was positive for *streptococcus mitis*. All cultures were negative for fungus. No serious postoperative complications occurred, including bacterial endophthalmitis, choroidal detachment, and retinal detachment.

CONCLUSION This preliminary study of office-based MIVS gives us insights on the microbiological profile and safety of performing such procedures outside the operating room controlled environment. Larger studies are needed to confirm our data before moving less complicated vitreoretinal surgeries into the office.

TAKE HOME MESSAGE Preliminary data shows the microbiological safety profile of office-based vitrectomy.

9:30 AM

Pars Plana Vitrectomy in the Management of Patients Diagnosed with Endophthalmitis Following Intravitreal Anti-VEGF Injection

- Juan M. Romero, MD
- Isaac Ezon, MD
- Khurram Chaudhary, MD
- David M. Fastenberg, MD
- Vincent A. Deramo, MD

OBJECTIVE Evaluate the possible benefit of pars plana vitrectomy in the treatment of patients with endophthalmitis following anti-VEGF injection.

PURPOSE Evaluate the possible benefit of pars plana vitrectomy in the treatment of patients with endophthalmitis following anti-VEGF injection.

METHODS We retrospectively reviewed the medical records of all patients in our practice with a diagnosis of endophthalmitis from January 1, 2007 through December 31, 2011. Only those with a clinical presentation consistent with endophthalmitis after intravitreal anti-VEGF injection were included. Clinical data that were collected and recorded included visual acuities (VA) as well as method of initial and subsequent treatment of endophthalmitis following anti-VEGF injection.

RESULTS Twenty-three patients met criteria. Nineteen patients received bevacizumab and 4 patients received ranibizumab. Median time from last injection to presentation was 4 days (range 1-18 days) with a median follow up of 10 months (range 1-44 months) after diagnosis of endophthalmitis. Seven patients had positive cultures. Median baseline VA (pre-endophthalmitis) was 20/100 (range 20/25 to CF at 2') with a median presenting VA of 1/150 (range 20/50 to LP vision). Ten patients underwent vitreous tap and injection of intravitreal antibiotics (TAP) only, 12 patients received TAP followed by pars plana vitrectomy (VIT), and 1 patient underwent VIT only. Final VA within 2 lines

of baseline VA or better was achieved in 15 patients (65%) and loss of 3 or more lines of VA in 8 patients (35%). Overall 90% (9 of 10) of the patients in the TAP only group regained VA within 1 line or better of baseline versus 42% (5 of 12) in the TAP and VIT group.

CONCLUSION Patients diagnosed with endophthalmitis after anti-VEGF intravitreal injection who underwent TAP regained baseline VA at least as often as those who underwent TAP and VIT. Our study did not support a benefit for immediate VIT in all patients, rather only in those cases of worsening VA. Our study suggests that TAP is a viable primary intervention for endophthalmitis after anti-VEGF injection.

TAKE HOME MESSAGE Patients presenting with endophthalmitis after anti-VEGF injection may be treated with vitreous tap and injection of intravitreal antibiotic. Those with who fail TAP may need to proceed to vitrectomy.