

## Vitreomacular Traction Syndrome

The vitreous humor is a transparent, gel-like material that fills the space within the eye between the lens and the retina. The vitreous is encapsulated in a thin shell called the vitreous cortex, and the cortex in young, healthy eyes is usually sealed to the retina.

As the eye ages, or in certain pathologic conditions, the vitreous cortex can pull away from the retina, leading to a condition known as posterior vitreous detachment (PVD). This detachment usually occurs as part of the normal aging process.

There are instances where a PVD is incomplete, leaving the vitreous partially attached to the retina, and causing tractional (pulling) forces that can cause anatomical damage. The resulting condition is called vitreomacular traction (VMT) syndrome.

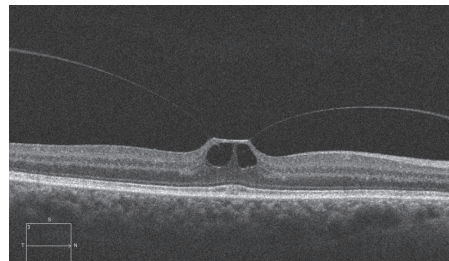
VMT syndrome can lead to different maculopathies or disorders in the macular area (at the center of the retina), such as full- or partial-thickness **macular holes**, **epiretinal membranes**, and **cystoid macular edema**. These disorders are often associated with reduced sharpness of vision (visual acuity) or other visual complications.

**Causes:** Age-related degeneration of the gel-like vitreous humor leads to the formation of pockets of fluid within the vitreous, causing contraction and loss of volume. The separation of the vitreous gel from the retina occurs as a result of the gel becoming liquid (*liquefaction*) and the continuous anterior-posterior (front-back) and tractional forces stretching on the **macula** over time.

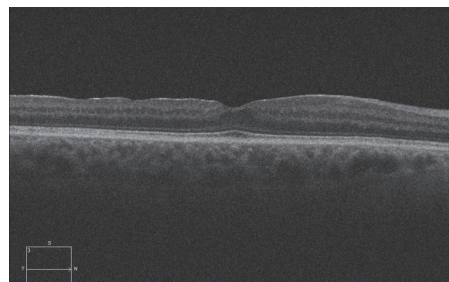
Weakening of the attachments of the vitreous cortex and the **internal limiting membrane** (ILM) of the retina could also lead to partial detachment of the posterior hyaloid membrane, leading to PVD and potentially VMT.

**Diagnostic Testing: Optical coherence tomography (OCT)** is a commonly used and recommended method to noninvasively identify and monitor VMT syndrome. This technology captures cross-sectional images of the retinal layers, including the surface, and allows physicians to evaluate the degree to which vitreomacular tractional forces are distorting the retinal structure.

*continued next page*



**Figure 1**  
SD-OCT appearance of right eye showing vitreomacular traction



**Figure 2**  
SD-OCT appearance of right eye following vitrectomy surgery

Images courtesy of Alex P. Hunyor, MD

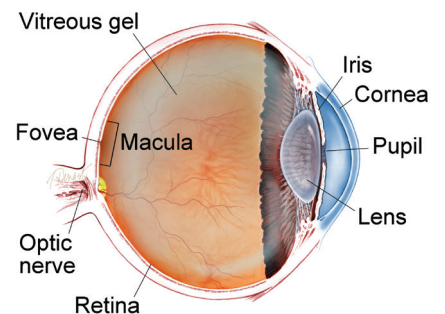
### SYMPTOMS IN DETAIL

**The most common symptoms experienced by patients with VMT syndrome are:**

- Decreased sharpness of vision
- Photopsia, when a person sees flashes of light in the eye
- Micropsia, when objects appear smaller than their actual size
- Metamorphopsia, when vision is distorted to make a grid of straight lines appear wavy or blank

Some of these symptoms can be mild and develop slowly; however, chronic tractional effects can lead to continued visual loss if left untreated. In some cases, a distortion of a visual picture could be experienced without necessarily having a reduction in sharpness of vision. ●

### WHAT IS THE RETINA?



**THE RETINA** is a thin layer of light-sensitive nerve tissue that lines the back of the eye (or vitreous) cavity. When light enters the eye, it passes through the iris to the retina where images are focused and converted to electrical impulses that are carried by the optic nerve to the brain resulting in sight.

## Vitreomacular Traction Syndrome continued from previous page

A **dynamic B-scan ultrasound** examination could also be performed to provide a detailed evaluation of the vitreoretinal interface.

**Treatment and Prognosis:** There are currently 3 main options for treating VMT syndrome.

1. Watchful waiting and regular monitoring with OCT is often used for patients whose symptoms do not warrant active intervention. Some cases of VMT may spontaneously resolve.
2. For patients whose symptoms are severe enough to require intervention, **pars plana vitrectomy surgery** is one treatment option. The procedure involves the manual release of vitreous attachment and alleviation of traction, but it is invasive and inconvenient to most patients. Therefore vitrectomy is reserved for patients who are at risk for severe visual disturbances and/or central blindness. Some studies have shown that shorter duration of symptoms results in better prognosis when the surgical treatment is employed.
3. Ocriplasmin (Jetrea®), a recombinant truncated form of human plasmin, is a pharmacologic option for treating VMT syndrome. Clinical trials demonstrated the efficacy and safety of a single intravitreal injection of ocriplasmin for the treatment of patients with symptomatic vitreomacular adhesion, and/or vitreomacular traction. Ocriplasmin is therefore a treatment option for some patients who have vitreomacular traction but who are not candidates for surgery.

Most patients with VMT maintain good visual acuity in the affected eye, even if treatment is required. ●

### Clinical Terms (appearing green within fact sheet text)

**Cystoid macular edema:** A painless disorder in which the **macula** becomes swollen with fluid (edema), that presents in cyst-like patterns.

**Dynamic B-scan ultrasound:** Sound waves are used to form an image of the back of the eye during ocular movements. This allows identification of spatial relationships of structures within the eye.

**Epi-retinal membrane:** A layer of scar tissue that forms on the surface of the macula that can warp and contract causing a wrinkling of the retina and distorted or decreased vision.

**Internal limiting membrane:** A very thin membrane on the innermost surface of the retina. Sometimes this membrane is removed at the time of vitrectomy.

**Macula:** A small area at the center of the retina where light is sharply focused to produce the detailed color vision needed for tasks such as reading and driving.

**Macular hole:** A hole in the *macula*, which is the small area at the center of the retina where light is sharply focused to produce the detailed color vision needed for tasks like reading. A full-thickness defect in the macula is referred to as a *macular hole*.

**Optical coherence tomography (OCT):** A non-invasive imaging technique that uses light to create a 3-dimensional image of your eye for physician evaluation.

**Retinal detachment:** A condition where the retina separates from the back of the eye wall. This may be caused by vitreous fluid leaking through a retinal tear or hole and collecting under the retina, causing it to separate from the tissue around it.

**Vitrectomy surgery (also referred to as pars plana vitrectomy):** A procedure undertaken by a specialist where the vitreous gel that fills the eye cavity is removed to provide better access to the retina. This allows for a variety of repairs, including the removal of scar tissue, laser repair of *retinal detachments* and treatment of *macular holes*. Once surgery is complete, a gas bubble or silicone oil may be injected into the vitreous gel to help hold the retina in position.

### RISK FACTORS

**VMT syndrome is most common in older adults and women due to age-related vitreous changes and vitreous liquefaction associated with declining post-menopausal estrogen levels, respectively.**

- Other risk factors include:
- High myopia (extreme nearsightedness)
- Exudative (wet) age-related macular degeneration
- Diabetic macular edema
- Retinal vein occlusion
- Diabetic retinopathy ●

### THANK YOU TO THE RETINA HEALTH SERIES AUTHORS

Sophie J. Bakri, MD  
 Audina Berrocal, MD  
 Antonio Capone, Jr., MD  
 Netan Choudhry, MD, FRCS-C  
 Thomas Ciulla, MD, MBA  
 Pravin U. Dugel, MD  
 Geoffrey G. Emerson, MD, PhD  
 Roger A. Goldberg, MD, MBA  
 Darin R. Goldman, MD  
 Dilraj Grewal, MD  
 Larry Halperin, MD  
 Vincent S. Hau, MD, PhD  
 Suber S. Huang, MD, MBA  
 Mark S. Humayun, MD, PhD  
 Peter K. Kaiser, MD  
 M. Ali Khan, MD  
 Anat Loewenstein, MD  
 Mathew J. MacCumber, MD, PhD  
 Maya Maloney, MD  
 Hossein Nazari, MD  
 Oded Ohana, MD, MBA  
 George Parlitsis, MD  
 Jonathan L. Prenner, MD  
 Gilad Rabina, MD  
 Carl D. Regillo, MD, FACS  
 Andrew P. Schachat, MD  
 Michael Seider, MD  
 Eduardo Uchiyama, MD  
 Allen Z. Verne, MD  
 Yoshihiro Yonekawa, MD

### EDITOR

John T. Thompson, MD

### MEDICAL ILLUSTRATOR

Tim Hengst