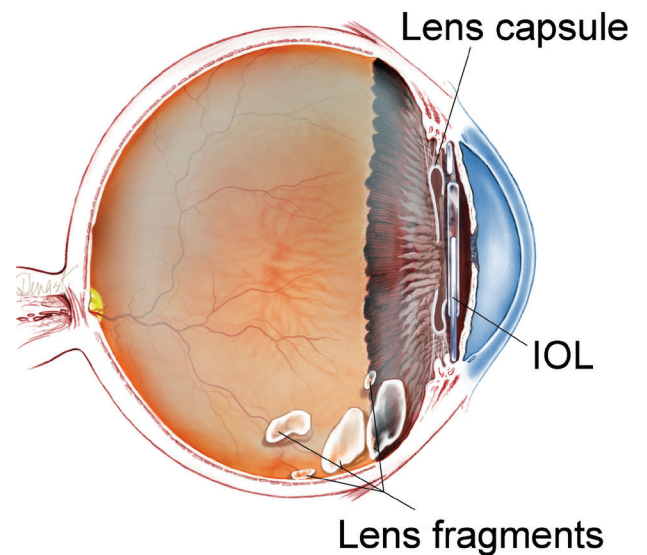


Retained Lens Fragments As people age, the lens of the eye develops a progressive opacification or clouding called a cataract. Cataracts are a significant cause of visual loss in older adults, and often surgery is performed when the lens causes vision loss to the point where it interferes with daily activities.

In most cases, cataract surgery is performed without complication. However, in some eyes, the cataract cannot be removed completely and fragments of the cataract may fall into the back of the eye where they cannot be safely removed by a cataract surgeon. Even the most skilled cataract surgeons have this happen—especially when the cataract is very firm or if trauma (injury) or other conditions have damaged the attachment of the lens to the inner wall of the eye.

When cataract pieces (or *lens fragments*) remain in the eye after surgery, a severe inflammatory reaction can occur that may cause high pressure in the eye, swelling in the center of the retina and cornea, and even potentially permanent visual loss. In these cases, additional surgery is performed by a vitreoretinal surgeon who can safely retrieve the cataract fragments from the back of the eye.

Proper timing of either medical or surgical follow-up care is crucial in providing the best possible outcome from this complication of cataract surgery.



continued next page

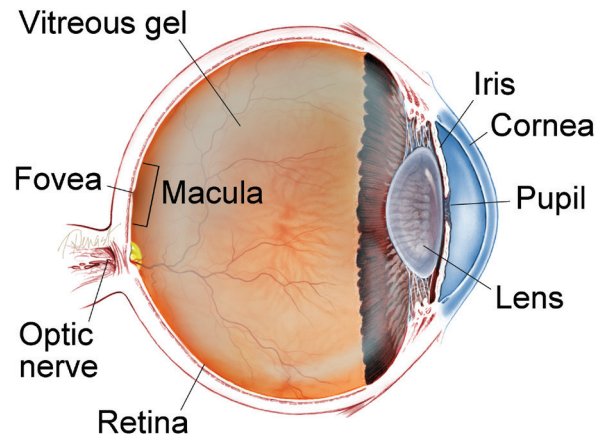
Retained Lens Fragments *continued from previous page*

Treatment and Prognosis: Again, proper timing and management become important in cases of retained lens material. Sometimes, surgery can be avoided with aggressive medical management using eye drops to reduce inflammation and elevated eye pressure, while allowing a small piece of cataract to dissolve on its own.

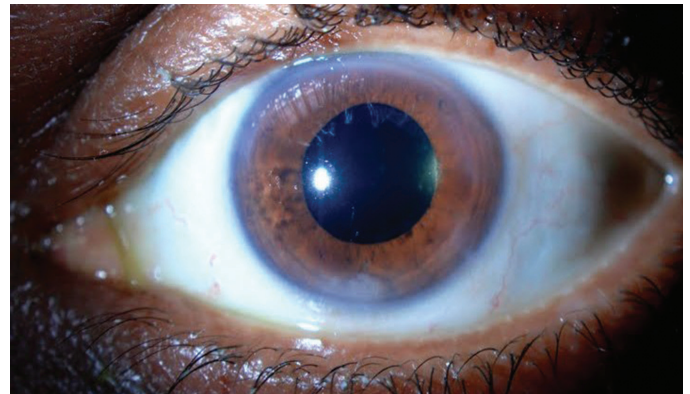
However, if the remaining lens material is significant or if the eye pressure remains elevated, additional surgery should be performed. A vitreoretinal surgeon typically performs a procedure called a **pars plana vitrectomy** to remove the lens material.

There is no consensus as to when a vitrectomy should be performed, but in general, vitrectomy is performed within 1 to 2 weeks after deciding that medical therapy with eye drops alone is not sufficient to solve the problem. Sometimes, an emergency vitrectomy has to be performed if the pressure in the eye remains very high despite medical therapy.

continued next page

WHAT IS THE RETINA?

THE RETINA is a thin layer of light-sensitive nerve tissue that lines the back of the eye (or vitreous) cavity. When light enters the eye, it passes through the iris to the retina where images are focused and converted to electrical impulses that are carried by the optic nerve to the brain resulting in sight.

**Retained Lens Fragments**

Jason Calhoun, MD. Mayo Clinic
Jacksonville Florida. Retina Image Bank
2013; Image 7743. ©American Society of
Retina Specialists.

Retained Lens Fragments *continued from previous page*

A vitrectomy is outpatient surgery where the eye's **vitreous gel** and remaining lens material are safely removed. The eye is filled at the end of surgery with saline (salt water) solution or a gas bubble, and the operation is typically very successful.

The surgery causes only mild pain and only a small percentage of patients require over-the-counter pain relievers after the procedure. The vision is cloudy following vitrectomy surgery while the eye heals, but gradually improves.

Complications are relatively uncommon after vitrectomy surgery, and include **retinal tears** or **retinal detachment** (1 in 100 patients). Infection and bleeding can also occur (about 1 in 2000 patients).

Patients who have vitrectomy surgery are monitored carefully afterward to watch for these potential complications. Most patients who require vitrectomy for retained lens fragments after cataract surgery achieve excellent vision. ●

SYMPTOMS**Patients with retained cataract material develop symptoms that may include:**

- Very blurry vision
- Eye pain from increased pressure
- Redness
- Sensitivity to light

Patients can almost always see the lens material in the form of large **floaters** or debris (scattered fragments) in their field of vision. ●

continued next page

Retained Lens Fragments *continued from previous page*

Clinical Terms (*appearing green within fact sheet text*)

Floater: Mobile blurry shadow that partially obscures vision. Floaters are most bothersome when near the center of vision and less annoying when they settle to the side of the vision. They may appear like cobwebs, dust, or a swarm of insects—or in the shape of a circle or oval, called a *Weiss ring*.

Retinal detachment: A condition where the retina separates from the back of the eye wall. This may be caused by vitreous fluid leaking through a retinal tear or hole and collecting under the retina, causing it to separate from the tissue around it.

Retina tear: A rip or discontinuity in the retina, which is the thin layer of light-sensitive nerve tissue that lines the back of the eye and is responsible for sight.

Vitrectomy surgery (also called pars plana vitrectomy surgery): A procedure undertaken by a specialist where the vitreous gel that fills the eye cavity is removed to provide better access to the retina. This allows for a variety of repairs, including the removal of scar tissue, laser repair of retinal detachments and treatment of macular holes. Once surgery is complete, saline, a gas bubble or silicone oil may be injected into the vitreous gel to help hold the retina in position.

Vitreous or vitreous humor: The “gel” that fills up the inside of the eye or vitreous cavity.

THANK YOU TO THE RETINA HEALTH SERIES AUTHORS

Sophie J. Bakri, MD
Audina Berrocal, MD
Antonio Capone, Jr., MD
Netan Choudhry, MD, FRCS-C
Thomas Ciulla, MD, MBA
Pravin U. Dugel, MD
Geoffrey G. Emerson, MD, PhD
Roger A. Goldberg, MD, MBA
Darin R. Goldman, MD
Dilraj Grewal, MD
Larry Halperin, MD
Vincent S. Hau, MD, PhD
Suber S. Huang, MD, MBA
Mark S. Humayun, MD, PhD
Peter K. Kaiser, MD
M. Ali Khan, MD
Anat Loewenstein, MD
Mathew J. MacCumber, MD, PhD
Maya Maloney, MD
Hossein Nazari, MD
Oded Ohana, MD, MBA
George Parlitsis, MD
Jonathan L. Prenner, MD
Gilad Rabina, MD
Carl D. Regillo, MD, FACS
Andrew P. Schachat, MD
Michael Seider, MD
Eduardo Uchiyama, MD
Allen Z. Verne, MD
Yoshihiro Yonekawa, MD

EDITOR

John T. Thompson, MD

MEDICAL ILLUSTRATOR

Tim Hengst