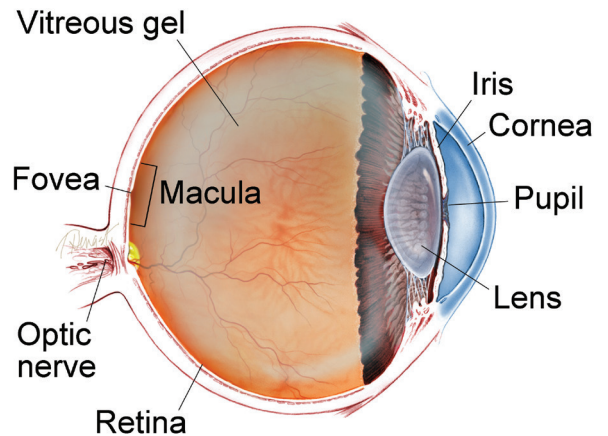


**Age-Related Macular Degeneration (AMD)** is a deterioration of the retina and **choroid** that leads to a substantial loss in visual acuity (sharpness of vision). AMD is the leading cause of significant visual acuity loss in people over age 50 in developed countries.

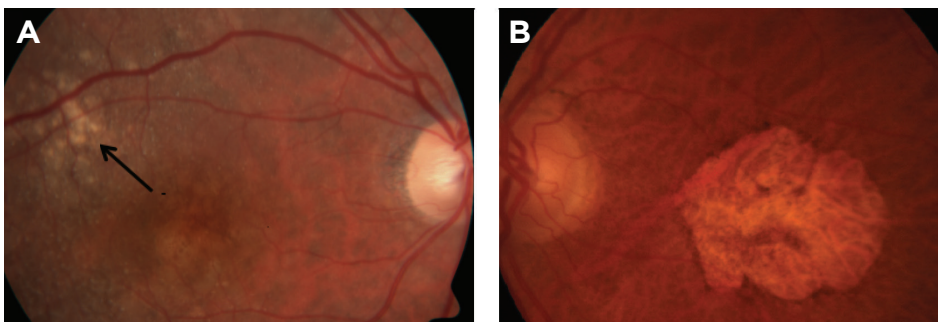
**Causes:** The exact cause of AMD is unknown, but the condition develops as the eye ages. There are 2 types of AMD: non-neovascular or *dry* AMD; and neovascular or *wet* AMD.

In early stages of dry AMD, the hallmark is *drusen*—pale yellow lesions formed beneath the retina (*Figure 1A*). Drusen are usually harmless, but as they accumulate, dry AMD can progress. Atrophic areas (areas of atrophy or wasting) in the retina also may develop; if the atrophic area is significant and with sharp borders, it is termed geographic atrophy (GA) (*Figure 1B*).

## WHAT IS THE RETINA?



**THE RETINA** is a thin layer of light-sensitive nerve tissue that lines the back of the eye (or vitreous) cavity. When light enters the eye, it passes through the iris to the retina where images are focused and converted to electrical impulses that are carried by the optic nerve to the brain resulting in sight.



**Figure 1**

Dry AMD.

**A.** Drusen (indicated by arrow).

**B.** Geographic atrophy

Photo courtesy

Anat Loewenstein, MD

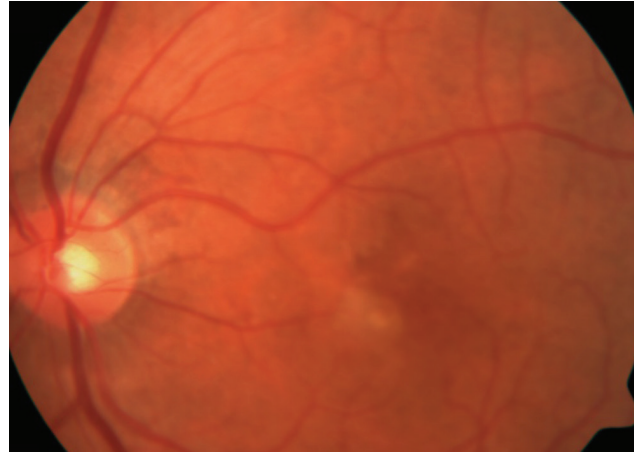
*continued next page*

**Age-Related Macular Degeneration** *continued from previous page*

GA is the advanced form of dry AMD, which may be associated with loss of central vision.

In wet AMD, there is a sudden or gradual decrease in visual acuity, blind spots in the center of vision, and distortion of straight lines. The hallmark of wet AMD is **choroidal neovascularization** (CNV) (*Figure 2*).

CNV occurs when abnormal blood vessels grow beneath the retina; these can bleed or leak and cause a distortion of the retina's structure. Ultimately, the CNV can turn into a **disciform scar** that replaces the normal architecture of the outer retina and leads to permanent loss of central vision.



**Figure 2**

Wet AMD. Choroidal neovascularization (indicated by arrow).

Photo courtesy Anat Loewenstein, MD

---

**Risk Factors:**

- Age—the strongest risk factor
- Caucasian race
- Family history of AMD
- Cigarette smoking

**Possible risk factors:**

- Female gender
- Lower level of education
- Light iris color
- Far-sightedness
- Cardiovascular (heart) disease
- High blood pressure
- High cholesterol
- Sunlight exposure
- Low dietary fish intake
- Higher body mass index (BMI)
- Having a diet low in lutein and zeaxanthin/antioxidants

*continued next page*

**Age-Related Macular Degeneration** *continued from previous page*

**Diagnostic Testing:** Disease features related to AMD may be found in the retina and in the layers beneath it. According to these abnormal findings, AMD is classified as dry or wet.

An AMD diagnosis is made by a clinical examination with a **slit lamp** and by using several types of imaging, including:

- **Fluorescein angiography** (FA)
- **Indocyanine green angiography** (ICGA)
- **Optical coherence tomography** (OCT)
- **Optical coherence tomography angiography** (OCTA)

**Treatment and Prognosis:** Wet-AMD treatment has been revolutionized in recent years after the discovery of *vascular endothelial growth factor* (VEGF), a family of compounds in the body. VEGF regulates the growth of abnormal new blood vessels in the eye—known as *neovascularization*—that can lead to wet AMD.

*Anti-VEGF* drugs have been developed to help stop neovascularization and preserve vision for AMD patients. There are currently 5 different anti-VEGF drugs:

- Avastin® (bevacizumab)
- Lucentis® (ranibizumab)
- Eylea® (aflibercept)
- Beovu® (brolucizumab)
- Vabysmo® (faricimab)

Wet AMD cannot be cured, but its progression may be blocked with the use of *intravitreal* (in-the-eye) anti-VEGF injections. These injections may preserve, and even recover, vision. Local anesthetic eye drops are given before the injections to numb the eye and minimize discomfort.

**SYMPTOMS**

**In early stages, AMD may have no symptoms at all. When the disease progresses, the symptoms are:**

- Distortion (warping) of straight lines
- A decrease in the intensity or brightness of colors

**As the macular degeneration progresses, AMD symptoms include:**

- A gradual or sudden loss of central vision, or
- Dark, blurry areas in the center of vision ●

*continued next page*

## Age-Related Macular Degeneration *continued from previous page*

There are 3 anti-VEGF treatment regimens commonly used for Avastin, Lucentis, Eylea, Beovu and Vabysmo. The best option is chosen in consultation with your retina specialist.

1. *Pro re nata* (PRN) or “treat and observe”—patients are treated with three initial monthly injections, followed by treatment as needed.
2. “Treat and extend”—after 3 initial monthly injections, the time between treatments is gradually increased as tolerated. Some eyes will continue to require monthly injections, but others can be treated less often as long as the wet AMD is controlled.
3. Monthly injections.

Before the first anti-VEGF drugs were introduced, wet-AMD patients were treated with **laser photocoagulation** or **photodynamic therapy** (PDT).

Anti-VEGF drugs have greatly improved wet-AMD treatment since 2005; patients today have a much better chance of maintaining their central vision so they can read, drive, recognize faces, and live normal lives.

No current treatment can prevent visual loss for patients with GA (the advanced form of dry AMD). However, the Age-Related Eye Disease Studies (AREDS), conducted by the National Eye Institute, have found that a nutritional supplement formula (AREDS-2 supplement) may delay and prevent intermediate dry AMD from moving to the advanced form.

The AREDS-2 supplement formula, which is widely available over the counter, contains specific doses of vitamins and minerals used in the AREDS-2 Study:

- Vitamin C
- Vitamin E
- Zinc
- Lutein
- Zeaxanthin

Although patients with either form of AMD can experience a progressive decrease in visual acuity, they will almost never be completely blind. ●

*continued next page*

## Age-Related Macular Degeneration *continued from previous page*

### Clinical Terms

*(appearing green within fact sheet text)*

**Choroid** (pronounced CORE oid): The layer of blood vessels and connective tissue between the retina and the white of the eye, also known as the *sclera*.

**Choroidal Neovascularization (CNV):** Growth of abnormal new blood vessels in the choroid layer of the eye that grow under the retina and macula and disrupt vision.

**Disciform scar:** A scar that develops in the macula area of the retina resulting from leakage and bleeding from abnormal blood vessels (neovascularization) in the eye.

**Fluorescein angiography (FA):** An imaging technique where a yellow dye called *sodium fluorescein* is injected into a vein in the arm, allowing a special camera to record circulation in the retina and *choroid* in the back of the eye. This test can be very useful in diagnosing a number of retinal disorders.

**Indocyanine green angiography (ICGA):** A diagnostic procedure that uses a green dye to illuminate blood flow in the choroid, which is a layer of blood vessels located between the white of the eye (*sclera*) and the retina that supplies nutrients to the inner eye.

**Laser photocoagulation:** A surgical technique that uses a highly targeted laser light to seal blood vessels and coagulate (clot) tissue.

**Optical coherence tomography (OCT):** A non-invasive imaging technique that uses light to create a 3-dimensional image of your eye for physician evaluation.

*continued next page*

Age-Related Macular Degeneration *continued from previous page***Clinical Terms***(appearing green within fact sheet text)*

**Optical coherence tomography angiography (OCTA):** A noninvasive imaging technique that uses light to image the blood vessels in different layers of the retina and choroid.

**Photodynamic therapy (PDT):** A treatment for macular degeneration in which a light-activated medicine (verteporfin) is injected into the bloodstream followed by application of a cold laser which targets abnormal blood vessels growing in the macula at the center of the retina.

**Slit lamp:** An instrument that combines a high-intensity light source with a microscope to examine the external and internal structures of the eye, including the optic nerve and retina.

**THANK YOU TO THE  
RETINA HEALTH SERIES  
AUTHORS**

Sophie J. Bakri, MD, FASRS  
Audina Berrocal, MD, FASRS  
Antonio Capone, Jr., MD  
Netan Choudhry, MD, FRCS-C, FASRS  
Thomas Ciulla, MD, MBA, FASRS  
Pravin U. Dugel, MD, FASRS  
Geoffrey G. Emerson, MD, PhD, FASRS  
K. Bailey Freund, MD  
Roger A. Goldberg, MD, MBA, FASRS  
Darin R. Goldman, MD  
Dilraj Grewal, MD, FASRS  
Larry Halperin, MD, FASRS  
Vivienne S. Hau, MD, PhD, FASRS  
Suber S. Huang, MD, MBA, FASRS  
G. Baker Hubbard, MD, FASRS  
Mark S. Humayun, MD, PhD  
Talia R. Kaden, MD  
Peter K. Kaiser, MD, FASRS  
M. Ali Khan, MD, FASRS  
Ivana K. Kim, MD, FASRS  
Eleonora Lad, MD, PhD  
Anat Loewenstein, MD  
Mathew J. MacCumber, MD, PhD, FASRS  
Maya Maloney, MD  
Timothy G. Murray, MD, MBA, FASRS  
Hossein Nazari, MD  
Oded Ohana, MD, MBA  
Jonathan L. Prenner, MD, FASRS  
Gilad Rabina, MD  
Carl D. Regillo, MD, FACS, FASRS  
Naryan Sabherwal, MD  
Sherveen Salek, MD  
Andrew P. Schachat, MD  
Adrienne W. Scott, MD, FASRS  
Michael Seider, MD  
Janet S. Sunness, MD  
Eduardo Uchiyama, MD, FASRS  
Allen Z. Verne, MD, FASRS  
Christina Y. Weng, MD, MBA, FASRS  
Yoshihiro Yonekawa, MD, FASRS

**EDITOR**

John T. Thompson, MD

**MEDICAL ILLUSTRATOR**

Tim Hengst