

1:05 PM

96 Weeks Results from the VIEW 1 and VIEW 2 Studies: Intravitreal Aflibercept Injection Versus Ranibizumab for Neovascular AMD

- Allen C. Ho, MD
- Victor Chong, MD

OBJECTIVE Results at 96 weeks from two large wet AMD studies, VIEW 1 and VIEW 2, will provide additional understanding of the benefit of Intravitreal Aflibercept Injection relative to ranibizumab.

PURPOSE To evaluate the efficacy and safety of intravitreal aflibercept injection (IAI; also referred to as VEGF Trap-Eye) vs ranibizumab up to 96 weeks in the Phase 3 VIEW 1 and VIEW 2 studies.

METHODS Patients in both studies were randomized to ranibizumab 0.5 mg every month (Rq4), IAI 2 mg every month (2q4), 0.5 mg every month (0.5q4), or 2 mg every 2 months (2q8) following 3 initial monthly doses over the first 52 weeks. From Weeks 52 to 96, patients were dosed at least quarterly with more frequent dosing allowed based on predetermined retreatment criteria. Week 96 outcomes included the proportion of patients who maintained visual acuity (VA) (loss of <15 ETDRS letters) and mean change from baseline in best-corrected visual acuity (BCVA). Data from integrated analyses are reported here.

RESULTS At Week 96, for the Rq4, IAI 2q4, IAI 0.5q4, and IAI 2q8 groups, proportions of patients maintaining VA were 92%, 92%, 91%, and 92%, respectively; mean BCVA gains were 7.9, 7.6, 6.6, and 7.6 letters, with averages of 16.5, 16.0, 16.2, and 11.2 injections over two years and 4.7, 4.1, 4.6, and 4.2 injections over the follow-up period after Week 52, respectively. The proportion of patients who required frequent injections

(≥ 6) in the second year was lower in both the 2q4 and 2q8 groups compared with Rq4 (14.0% and 15.9% vs 26.5%, respectively). In the 25% of patients who required the most intense therapy (greatest number of injections), the 2q4 and 2q8 groups required an average of 1.5 and 1.4 fewer injections compared with Rq4 (6.5 and 6.6 vs 8.0, respectively). The incidence of ocular and systemic adverse events was balanced across treatment groups. The most frequent ocular adverse events ($>10\%$ of patients) were conjunctival hemorrhage, eye pain, retinal hemorrhage, and VA reduced.

CONCLUSION Visual improvements achieved at Week 52 were largely maintained through Week 96 with both intravitreal aflibercept and ranibizumab injections. The original 2q8 aflibercept group achieved efficacy results that were similar to ranibizumab, with an average of 5.3 fewer injections over the 96 week period. Intravitreal aflibercept had a generally favorable safety profile through Week 96.

TAKE HOME MESSAGE The visual acuity improvements achieved at Week 52 were largely maintained through Week 96 with both intravitreal aflibercept and ranibizumab injections.

1:13 PM

The Incidence of Non-Infectious Intraocular Inflammation after Intravitreal Aflibercept Injection



- Daniel B. Roth, MD
- Jonathan L. Prenner, MD
- Howard F. Fine, MD, MHSc
- Stuart N. Green, MD
- David L. Yarian, MD

OBJECTIVE The purpose of this study was to examine the nature and incidence of noninfectious intraocular inflammation associated with intravitreal aflibercept injection.

PURPOSE Aflibercept has recently been approved as a potent inhibitor of vascular endothelial growth factor (VEGF) for the treatment of neovascular AMD. The development of noninfectious intraocular inflammation after intravitreal aflibercept injection (IAI) has been reported. We evaluated the incidence of intraocular inflammatory reactions after IAI during our first 120 days of use.

METHODS Every eye receiving IAI was consented and prepared in an identical fashion to our protocol for VEGF inhibitors. The eye was numbed either with topical 4% lidocaine or subconjunctival 2% lidocaine. All eyes were injected in the superotemporal quadrant after placement of topical 5% povidine-iodone solution. All eyes, whether they were

treatment naïve or had received prior injections of VEGF inhibitors, were evaluated within 1 week of receiving IAI.

RESULTS 477 eyes in 372 patients were treated; 38 eyes received more than one injection and 34 patients received injections in both eyes. Three eyes (0.6% of injections, 0.8% of patients) presented with symptomatic intraocular inflammation. The first patient reported pain and distortion and presented 4 days after her first IAI with mild anterior chamber (AC) cellular reaction without hypopyon or change in visual acuity (VA). Her symptoms resolved 7 days with the use of prednisolone drops. Two other patients presented 2 and 3 days after their first IAI with moderate AC inflammation, vitritis and intraretinal hemorrhages. VA was reduced from 20/40 to 20/80 and from 20/200 to HM, respectively. These 2 eyes were treated with a vitreous tap, which failed to grow any organisms, and intravitreal antibiotics followed by prednisolone drops. VA and inflammation improved slowly in the 2 later cases, but VA remained compromised to 20/60 and 9/200, respectively, one month after intravitreal antibiotics.

CONCLUSION Symptomatic noninfectious inflammation occurred in 0.6% of injections or 0.8% of patients in our early series of aflibercept use. Visual compromise and inflammation may persist for weeks and patients should be cautioned as to this, albeit uncommon, possibility.

TAKE HOME MESSAGE Noninfectious intraocular inflammation may occur after intravitreal aflibercept injection and the inflammation may take weeks to resolve.

1:25 PM

VEGF Trap-Eye (Aflibercept) Effectiveness in Wet AMD Patients Recalcitrant to Ranibizumab and Bevacizumab



- Vincent S. Hau, MD, PhD
- Rizwan A. Bhatti, MD
- Michael A. Samuel, MD
- Tom S. Chang, MD
- Michael J. Davis, MD
- Kevin K. Suk, MD
- Camille Harrison, MD

OBJECTIVE To present the functional and anatomic improvement outcomes of aflibercept intravitreal treatment in wet AMD eyes recalcitrant to multiple treatments of bevacizumab and/or ranibizumab.

PURPOSE To investigate the effect on visual acuity and macular thickness of intravitreal injections of 2.0 mg of aflibercept (Eylea) in eyes refractive to multiple treatments of bevacizumab and/or ranibizumab in exudative age-related macular degeneration (AMD).

METHODS This retrospective study investigated 20 patients with recalcitrant exudative AMD (defined as having leakage on SD OCT despite monthly 0.5 mg ranibizumab injections and/or 1.25 mg bevacizumab) after being treated with 2.0 mg aflibercept intravitreal injections. Treatment was given if any evidence of CNVM activity on FA, OCT, or clinical exam. At all visits, patients were followed with clinical examinations, Snellen visual acuities, and Spectralis OCTs. Periodic FAs and ICGs were also done prior to treatment and during follow-up.

RESULTS Prior to aflibercept treatment, fluid was seen on OCT (intraretinal, subretinal, or sub-RPE) in all 20 patients. The mean age was 82.6 with 50% males vs. females. On average, patients had at least 16.6 anti-VEGF injections (4.9 ranibizumab, 11.7 bevacizumab) prior to enrollment. At baseline, the median Snellen Va was 20/40 (range 20/25-20/300), mean central foveal thickness was 332.8 μm , and mean total volume was 8.63 mm^3 . Mean log MAR Va improved from 0.42 at pre-treatment to 0.372 at 1 month, and 0.329 at 2 months. Anatomically, mean central thickness and mean total volume improvement from baseline was 21.82 μm and 0.49 mm^3 respectively at 1 month and 60.25 μm and 0.53 mm^3 at 2 months. No unexpected adverse effects were seen during follow-up.

CONCLUSION Anatomic and visual acuity improvement was seen in patients given 2.0 mg aflibercept even in patients with persistent macular fluid after multiple monthly injections of ranibizumab and/or bevacizumab. This study supports the use of aflibercept as an effective treatment option for recalcitrant wet AMD patients to current standard anti-VEGF intravitreal injections.

TAKE HOME MESSAGE Aflibercept is an effective treatment option for patients with wet AMD recalcitrant to bevacizumab and/or ranibizumab.

1:29 PM

The Initial Response to Aflibercept for Neovascular AMD with Persistent Fluid on OCT (Non-Responders)

- Patrick Dewey Williams, MD
- David Callanan, MD
- Robert C. Wang, MD
- Deborah Yeh Chong, MD

OBJECTIVE This retrospective review examines the initial response to aflibercept in patients with neovascular AMD and persistent fluid on OCT after treatment with ranibizumab or bevacizumab.

PURPOSE Do patients with neovascular AMD and persistent fluid on OCT after treatment with ranibizumab or bevacizumab have anatomic or clinical improvement after aflibercept treatment?

METHODS Criteria for selection in the retrospective review included neovascular AMD with persistent fluid on OCT after anti-VEGF treatment, intravitreal injection of aflibercept, previous anti-VEGF injection within four months of aflibercept injection, and OCT performed pre-injection and one month post-injection. Any patient with a central disciform scar, confounding maculopathy such as epiretinal membrane, previous endophthalmitis, or previous vitrectomy was excluded. Snellen visual acuity, OCT foveal thickness, and OCT macular volume were recorded pre-injection and at one month post-injection. OCT cross sections at the one-month visit were reviewed for resolution of fluid.

RESULTS 183 patients were initially reviewed. 55 eyes of 54 patients were included in the study. They received a mean of 13 previous anti-VEGF injections. The average time from previous anti-VEGF to aflibercept was 48 days. The median pre-injection vision (VA) was 20/50. At the one-month visit, the median VA was 20/40. 24 eyes gained at least

one line of vision, while 24 maintained vision and 6 lost at least one line. The mean foveal thickness (FT) improved from 351 μ m to 300 μ m. Of the 44 patients with macular volume (MV) data, the mean improvement was from 7.72mm³ to 7.25mm³. Both FT and MV changes were statistically significant based on a two-tailed paired t-test ($p < 0.001$ for both). 17 patients had no residual fluid on OCT. In 31 eyes that had previous anti-VEGF injection with 6 weeks of aflibercept, the median VA changed from 20/60 to 20/50. The FT improved from 333 to 302 μ m ($p < 0.05$). The MV change (7.64 to 7.49mm³) in the 24 eyes with data was not significant ($p = 0.10$).

CONCLUSION The results suggest that one injection of aflibercept may reduce persistent fluid on OCT. Snellen visual acuities were roughly equivalent pre-and-post injection. In a retrospective review of cases deemed "failures" the possibility of bias must be considered. Whether or not improved OCT data reduces the risk of future vision loss in these patients is still unclear.

TAKE HOME MESSAGE In patients with neovascular AMD, aflibercept may reduce persistent fluid on OCT while maintaining visual acuity.

1:33 PM

Resolution of Persistent Macular Edema, SRF and/or RPE Detachment After Single Injection of Aflibercept in Patients with Neovascular AMD



- Ashish G. Sharma, MD, FACS
- Cheryl Ryan, CCRC, COA, OSA
- Cheryl Kiesel, CCRC
- Joseph P. Walker, MD, FACS
- Glenn L. Wing, MD, FACS
- Paul A. Raskauskas, MD, FACS
- Tom Ghuman, MD, FACS

OBJECTIVE To demonstrate the benefit of aflibercept in patients with chronic neovascular AMD and associated pathology.

PURPOSE To study visual outcomes and Optical Coherence Tomography (OCT) findings after single intravitreal injection of aflibercept in patients with neovascular age-related macular degeneration (AMD) and persistent macular edema, subretinal fluid, and/or

retinal pigment epithelial (RPE) detachment despite multiple treatments of ranibizumab and/or bevacizumab.

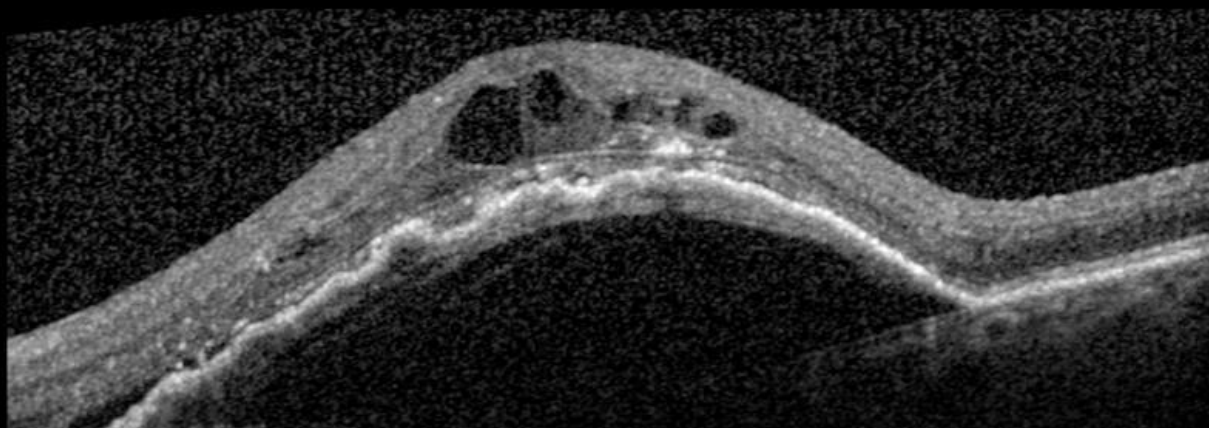
METHODS A retrospective chart review was performed of 21 patients with neovascular AMD who received multiple treatments of ranibizumab and/or bevacizumab and had persistent macular edema, subretinal fluid, and/or retinal pigment epithelial detachment. These patients underwent an intravitreal injection of aflibercept. Data such as gender, age, visual acuity, macular pathology, OCT central foveal thickness, treatment history, and follow up period were collected.

RESULTS At the onset of aflibercept injection: 14% (3/21) had predominantly persistent macular edema, 9% (2/21) had persistent subretinal fluid, 29% (6/21) had persistent RPE detachment, and 48% (10/21) had a combination. At the one month post aflibercept visit, 67% (2/3) of subjects with persistent macular edema had marked improvement and 33% (1/3) had complete resolution. All subjects with persistent subretinal fluid (2/2) had complete resolution. Of the 6 subjects with persistent RPE detachment, 33% (2/6) showed no improvement, 33% (2/6) showed marked improvement, and 33% (2/6) resolved completely. Of the 10 patients with a combination, 20% (2/10) had no improvement, 30% (3/10) had marked improvement, and 50% (5/10) completely resolved. Thirty eight percent (8/21) of patients experienced improved vision, 19% (4/21) experienced a decrease, and 43% (9/21) experienced no change. Nine of 21 patients (43%) had complete resolution of macular edema, subretinal fluid, and/or RPE detachment.

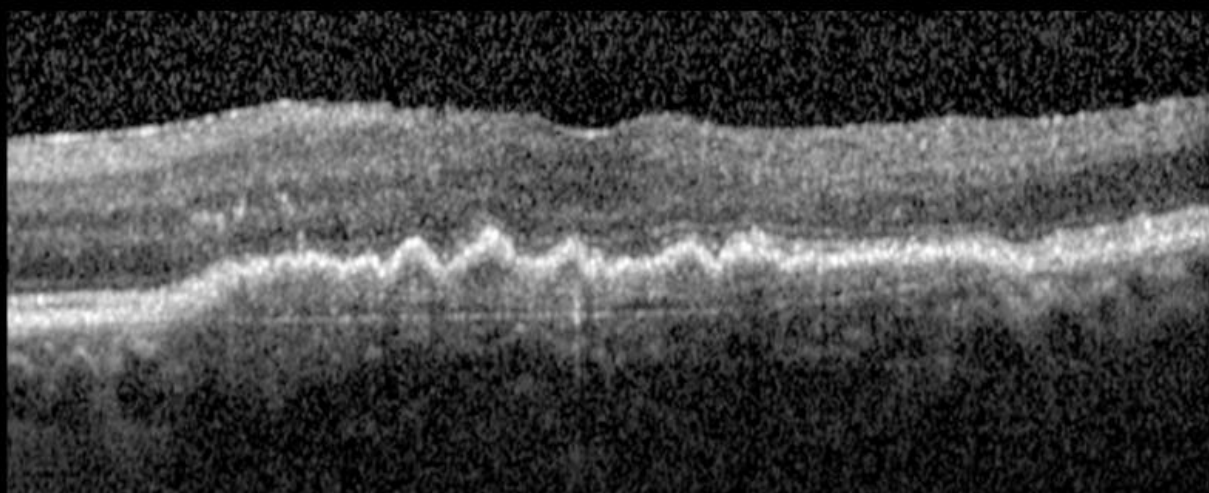
CONCLUSION Patients with neovascular AMD respond well to the anti-VEGF therapies of ranibizumab and bevacizumab. There is a subset of patients that have persistent macular edema, subretinal fluid, and/or RPE detachment despite multiple treatments and may respond to aflibercept. Almost half of our subjects had complete resolution of their macular pathology after single aflibercept injection.

TAKE HOME MESSAGE Patients with persistent macular edema, subretinal fluid, and/or RPE detachment from neovascular AMD with history of multiple ranibizumab and/or bevacizumab treatments may respond well to aflibercept.

PRIOR TO AFLIBERCEPT



ONE MONTH POST AFLIBERCEPT



1:37 PM

Pigment Epithelial Detachment Improvement in Non-Naive Neovascular AMD Patients After Intravitreal Aflibercept

- James C. Major, MD, PhD FACS
- Angeline F Mariani, BA
- Charles C. Wykoff, MD, PhD
- David M. Brown, MD

OBJECTIVE To examine the effect of a highly specific anti-VEGF agent, aflibercept, on persistent PEDs associated with CNV secondary to AMD in patients previously receiving multiple anti-VEGF injections.

PURPOSE The purpose of this study was to examine the effect of aflibercept, a novel high affinity anti-VEGF agent, on the improvement of recalcitrant PEDs in AMD patients that had received previous injections of bevacizumab and ranibizumab with little to no effect.

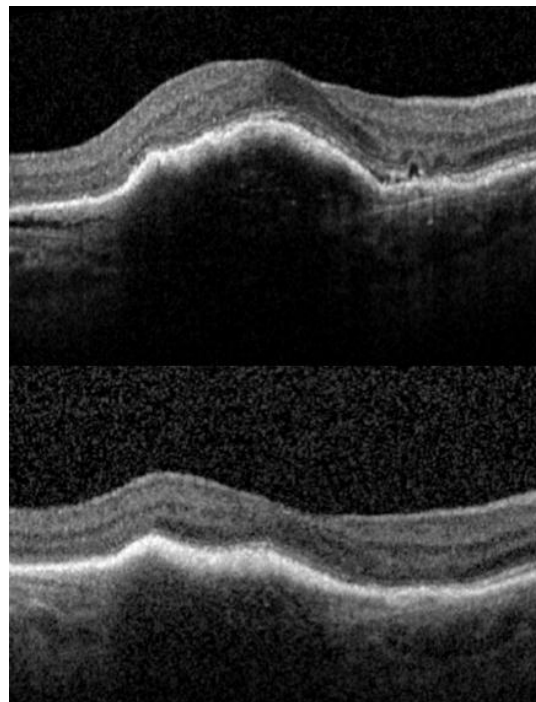
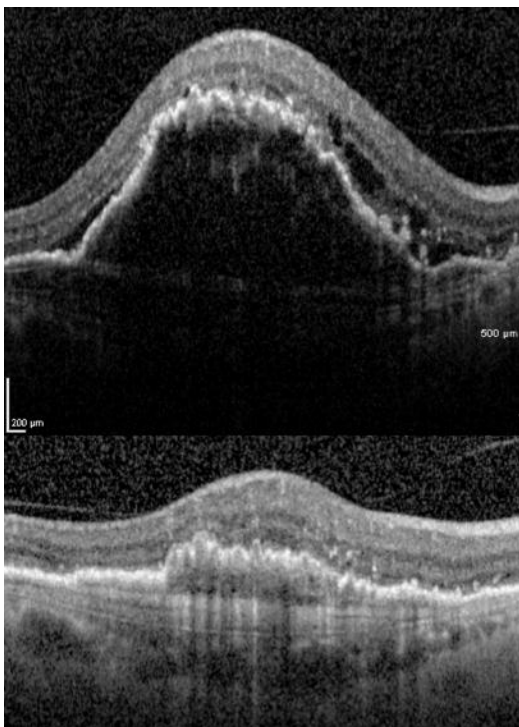
METHODS This retrospective, comparative, nonrandomized SD-OCT and chart review included 64 patients with persistent PEDs associated with CNV secondary to neovascular AMD. Patients included received two or more previous intravitreal injections of bevacizumab or ranibizumab with no PED change noted on exam or SD-OCT quantitative review. Data were pooled from six retina physicians from six practice locations. Endpoints were mean changes in SD-OCT quantitative PED height at one week and one month after initial aflibercept injection.

RESULTS A total of 100 visits were assessed at week one, month one, or at both endpoints after aflibercept injection. Of these visits, overall PED improvement was noted in 57 visits (57%), using the day of injection as baseline. 27 of 40 eyes (67.5%) showed statistically significant improvement of at least 10 microns in SD-OCT PED height at one week follow up. 30 of 60 eyes (50%) showed significant improvement of at least 10 microns in SD-OCT PED height at one month follow up. Of the eyes with both

endpoints, about half of the eyes that showed improvement at week one maintained this improvement by month one. 29 was the mean number of previous anti-VEGF injections for patients who did not maintain initial improvement by month one. Patients who had no initial PED response received a mean of 32 previous intravitreal injections. Thus, there was an inverse correlation between overall number of injections and PED response.

CONCLUSION Intravitreal aflibercept resulted in a significant reduction in persistent PEDs in patients previously receiving multiple intravitreal injections of bevacizumab and/or ranibizumab. As PEDs contribute to the vision loss and scarring seen in neovascular AMD, a timely and more complete resolution results in minimization of residual pathology as well as visual acuity gains for AMD patients.

TAKE HOME MESSAGE Resolution and improvement in persistent PEDs in Wet AMD can be achieved through a highly selective anti-VEGF agent Aflibercept.



1:49 PM

Aflibercept for Patients Previously Treated With Anti-VEGF Therapy for Age-Related Macular Degeneration

- Irene A. Barbazetto, MD
- Michael Engelbert, MD, PhD
- John Alan Sorenson, MD

OBJECTIVE Short-term follow-up of aflibercept therapy for non-treatment naive AMD patients showed stabilization of visual acuity and improvement of central macular thickness.

PURPOSE To evaluate the short-term outcomes after intravitreal aflibercept (Eylea; Regeneron Pharmaceuticals, Inc.) injection in patients who had been previously treated with antiVEGF therapy for neovascular age-related macular degeneration.

METHODS A review of data for consecutive patients who received intravitreal aflibercept injection was conducted. The main outcome measures were mean visual acuity, central macular thickness, presence of subretinal fluid, cystic changes and pigment epithelial detachment on optical coherence tomography (OCT). Response to aflibercept therapy was evaluated with particular attention to prior treatment with ranibizumab or bevacizumab (Lucentis; Genentech, Inc.).

RESULTS Mean baseline visual acuity of 61 eyes of 50 patients was 0.67 LogMar (STDEV 0.46), and all patients had undergone prior treatment with intravitreal antiVEGF therapy. Mean visual acuity at follow-up (1 to 4 months, average 1.7) was 0.66 LogMar (STDEV 0.48) ($P = 0.44$). Mean baseline central macular thickness was 342 microm and improved to 266 microns at 3 months ($P < 0.001$) in patients who had at least 3 months of follow up. 37 patients (74%) were treated with monthly injections, the remaining patients were treated based on a “treat and extend” protocol. Treatment was well tolerated with no adverse events reported.

CONCLUSION Short-term results of aflibercept therapy showed stabilization of, but no improvement in, mean visual acuity. Central macular thickness in patients with at least 3 months follow-up decreased significantly. Further studies are needed to determine if patients stabilized with other antiVEGF agents require 3 monthly loading doses of aflibercept.

TAKE HOME MESSAGE Short-term follow-up of aflibercept therapy for non-treatment naive AMD patients showed stabilization of visual acuity and improvement of central macular thickness.

1:53 PM

Initial Experience With Aflibercept in the Management of Patients With Persistent Exudation Due to AMD Undergoing Chronic Ranibizumab Therapy



- Kirk H. Packo, MD, FACS

OBJECTIVE To determine the effect of a single injection of aflibercept on patients with chronic recalcitrant fluid despite multiple prior consecutive injections of ranibizumab in age-related macular degeneration

PURPOSE Although therapy of choroidal neovascularization with ranibizumab (RB) has revolutionized AMD management, the need to treat patients chronically is common. Often patients maintain constant subretinal, intraretinal and sub RPE fluid despite frequent injections of RB. This review reports initial experience in the transition of patients with chronic fluid on RB therapy to the first injection of AF.

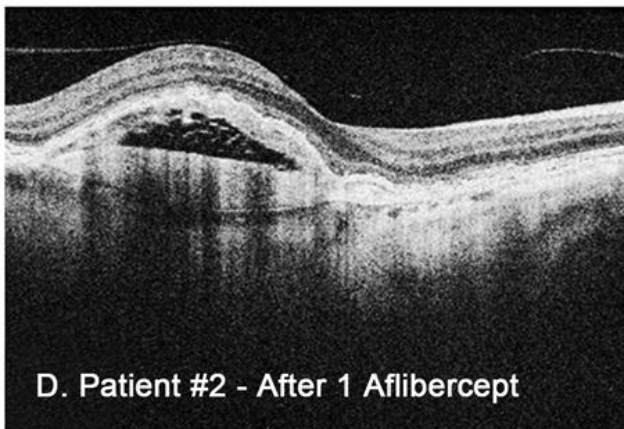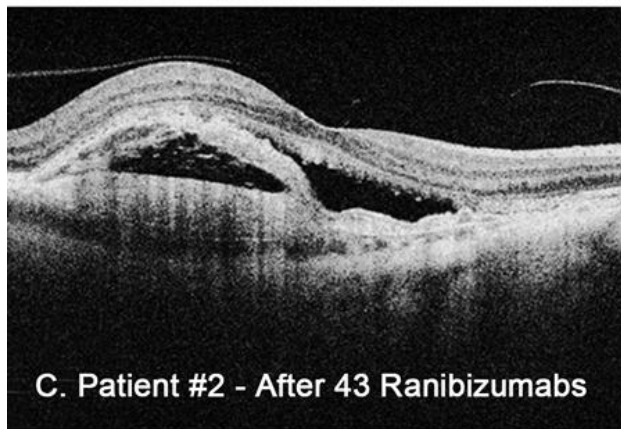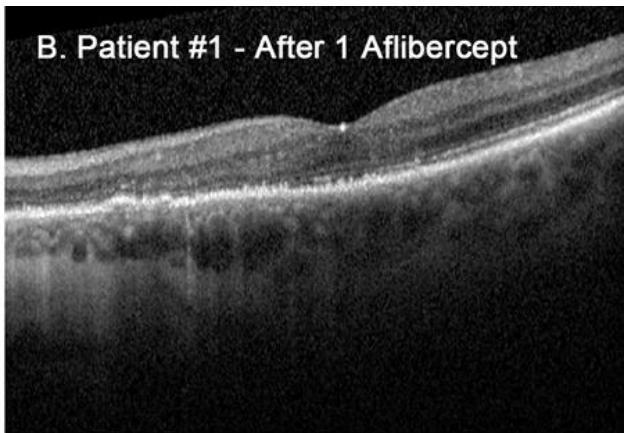
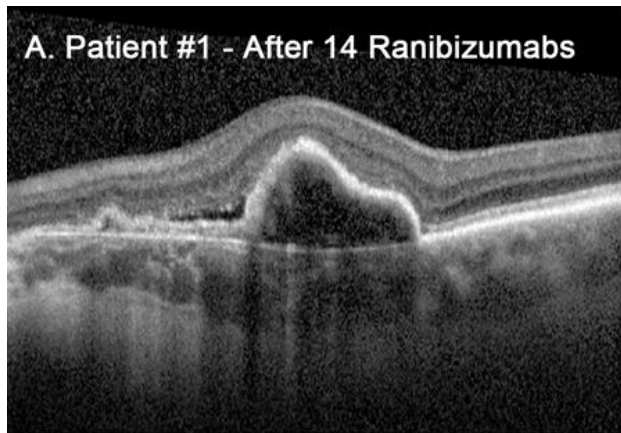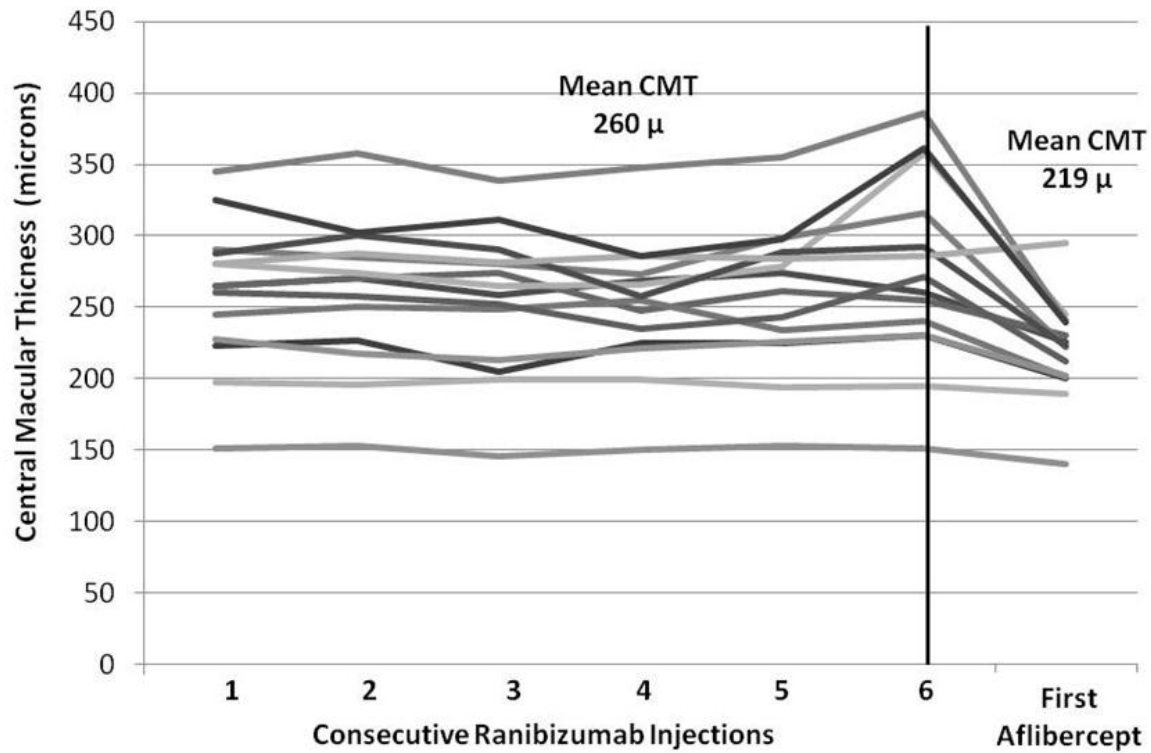
METHODS A retrospective review was performed in all patients treated by the author for exudative AMD undergoing "on demand" therapy with ranibizumab during a period of January 1, 2012 to March 25, 2012. All patients were being evaluated every 4-6 weeks with spectral domain OCT, and RB injections were given only if fluid was noted. 14 patients were identified that showed chronic intraretinal, subretinal, and/or subRPE fluid despite at least six consecutive treatments with RB. Any patients that had a skip in therapy due to lack of fluid were excluded. All 14 patients were given a single injection of aflibercept and re-evaluated 4-6 weeks later with visual acuity and OCT.

RESULTS The study group was comprised of 8 males/6 females with mean age 81 (75-90). Treating in "on demand" fashion, patients had a mean of 25 TOTAL prior RB injections (range 6-45) and 19 CONSECUTIVE RB injections (range 6-43) during which time some fluid was always noted. After AF injection, 13/14 (93%) showed total or near total resolution of intraretinal (IRF) and subretinal fluid (SRF). 11/14 (79%) showed total resolution of IRF/SRF. 2/14 showed partial resolution of IRF/SRF. Only 1/14 showed no fluid reduction. 6/14 patients showed subRPE fluid (RPED) prior to AF, and of these, 3/6 showed resolution of the RPED. Mean central macular thickness (CMT) prior to AF injection was 260 μ . After AF injection, CMT reduced to a mean of 219 μ . The mean acuity during the RB injections was 20/83 (20/20 to 20/162). After AF, the mean acuity was 20/74 (20/20 to 20/150). At the time of abstract submission, results after the second AF injection were unavailable but will be presented at the meeting.

CONCLUSION Aflibercept appears to be a powerful rescue therapy for patients with chronic fluid recalcitrant to ranibizumab. Sub-RPE fluid is more resistant. The effect of decreasing placental growth factor (PlGF) with AF may play a role. Although no visual gain was seen, it seems likely that removal of chronic fluid is beneficial. More experience is needed to see the continued effect of AF over time.

TAKE HOME MESSAGE Aflibercept may be a useful drug to remove chronic intraretinal and subretinal fluid that is recalcitrant to standard anti-VEGF therapy.

Change in Central Macular Thickness After Six Consecutive Ranibizumab Injections and One Aflibercept Injection



1:57 PM

Intravitreal Aflibercept in Eyes with Active Choroidal Neovascularization (CNV) Secondary to AMD After Multiple Ranibizumab or Bevacizumab Injections

- Harold M. Wheatley, MD
- Marisa Lau, BS
- Howard F. Fine, MD, MHSc
- Daniel B. Roth, MD
- Jonathan L. Prenner, MD

OBJECTIVE To evaluate the effect of one dose of aflibercept in eyes with active CNV after treatment with persistent ranibizumab and or bevacizumab injections.

PURPOSE Aflibercept is an anti-VEGF fusion protein that has been proven efficacious in treatment naïve eyes with CNV secondary to AMD. We sought to determine if aflibercept would be effective in treatment-experienced eyes that had persistent CNV activity secondary to AMD after multiple anti-VEGF antibody injections.

METHODS After IRB approval was obtained, a retrospective chart review of a consecutive series of 43 eyes of 43 patients was performed. All eyes were treated by a single investigator (JP) and had active CNV as determined by the presence of subretinal fluid and or cystoid macular edema on spectral domain optical coherence tomography (OCT) after an initial angiographic diagnosis of CNV. All eyes had received multiple anti-VEGF injections before being given aflibercept. The main outcome measures included change in visual acuity and OCT parameters.

RESULTS The cohort received an average of 21.6 anti-VEGF injections (17.4 ranibizumab, 4.2 bevacizumab) before being injected with aflibercept. These patients were being treated with anti-VEGF therapy consistently, and were last injected with ranibizumab or bevacizumab 5.2 weeks (mean) before the aflibercept injection (range 5-6 weeks).

Snellen visual acuity improved significantly after one injection, from 20/71.5 before aflibercept to 20/62.6, five weeks after the injection ($p=.043$) . OCT central subfield thickness decreased significantly after one injection, from 278.3 μm before aflibercept to 252.8 μm five weeks after the injection ($p=.032$) . OCT volume decreased significantly after one injection, from 9.58 mm^3 before aflibercept to 9.27 mm^3 five weeks after the injection ($p=.0003$) . Qualitative OCT assessment demonstrated anatomic normalization in 12 eyes (28%), improvement in 11 eyes (26%), no change in 16 eyes (37%), and worsening anatomy in 4 eyes (9%).

CONCLUSION A single dose of aflibercept provided significant anatomic and visual improvement in a cohort of eyes that had persistent CNV activity from AMD after multiple injections of ranibizumab and or bevacizumab. Marked anatomic improvement or normalization of anatomy by OCT occurred in 53.5% of treated eyes after one injection of aflibercept.

TAKE HOME MESSAGE Intravitreal aflibercept is effective in treating eyes with CNV secondary AMD that have not completely responded to sequential anti-VEGF antibody therapy.

2:01 PM

Aflibercept for Exudative AMD Suboptimally Responsive to Ranibizumab and Bevacizumab



- Chirag P. Shah, MD, MPH
- Hyung Cho, MD
- Tina S. Cleary, MD
- Juanita S. Bryant, MD
- Torsten W. Wiegand, MD, PhD
- Michael G. Morley, MD
- Trexler M. Topping, MD
- Jeffrey S. Heier, MD

OBJECTIVE A significant proportion of exudative AMD cases with persistent fluid on OCT despite regular ranibizumab and/or bevacizumab treatment respond anatomically to aflibercept.

PURPOSE To evaluate the anatomic and visual effect of one intravitreal aflibercept injection in cases of exudative AMD with persistent fluid on OCT despite regular ranibizumab and/or bevacizumab treatment.

METHODS Charts at Ophthalmic Consultants of Boston, Boston, MA, were retrospectively reviewed between November 19, 2012 and March 13, 2012. This study included all

consecutive eyes with exudative AMD treated with intravitreal aflibercept after previous treatment with regular ranibizumab and/or bevacizumab injections. Eyes were included only if spectral-domain OCT exhibited persistent fluid during ranibizumab/bevacizumab treatment before crossover to aflibercept. Tabulated data included prior treatments, non-best-corrected visual acuity, central subfoveal thickness on registered spectral domain OCT before and after aflibercept injection, and macular description before and after aflibercept injection.

RESULTS 32 eyes met inclusion/exclusion criteria and were deemed suboptimally responsive to an average of 13 regular ranibizumab/bevacizumab injections. 78% (25 eyes) showed anatomic improvement after a single intravitreal aflibercept injection. The majority of these eyes had improvement or resolution of previously recalcitrant subretinal fluid (76%, 19 eyes). Five eyes had improvement of persistent intraretinal fluid. One showed improved choroidal fluid with a smaller pigment epithelium detachment. Mean follow-up time was 37 days (range 27 to 49) after patients' first aflibercept injection. Central subfoveal thickness improved from 304 to 280 microns ($p = 0.005$). Non-best-corrected visual acuity did not improve significantly (logMAR 0.55 to 0.46, Snellen 20/71 to 20/58, $p = 0.13$).

CONCLUSION A significant proportion of exudative AMD cases with persistent fluid on OCT despite regular ranibizumab and/or bevacizumab treatment respond anatomically to aflibercept. There was a non-significant improvement in visual acuity. Data collection is ongoing with 97 suboptimally responsive eyes crossed over aflibercept currently; the complete dataset with follow-up will be presented at ASRS 2012.

TAKE HOME MESSAGE A significant proportion of exudative AMD cases with persistent fluid on OCT despite regular ranibizumab and/or bevacizumab treatment respond anatomically to aflibercept.

2:05 PM

Initial Early Clinical Experience With Aflibercept for Wet Age-Related Macular Degeneration



- Philip J. Ferrone, MD
- David M. Fastenberg, MD
- Vincent Deramo, MD
- Kenneth B. Graham, MD

OBJECTIVE Initial clinical experience with Aflibercept for the treatment of wet Age Related Macular Degeneration.

PURPOSE To review our initial clinical experience with Aflibercept for the treatment of wet Age Related Macular Degeneration using over 1,700 drug doses.

METHODS A retrospective record review was performed to look at all patients treated with Aflibercept for wet Age Related Macular Degeneration (wARMD) in our practice. The patients were treated since the drug was approved for use by the Food and Drug Administration (FDA) until present. Most patients were converted from other Anti-Vascular Endothelial Factor (Anti-VEGF) drugs, which included Bevacizumab and Ranibizumab. We reviewed all treated patients to assess for changes in vision (Snellen),

Central Foveal Thickness (CFT), response to drug, and any inflammation or endophthalmitis.

RESULTS Over 1,700 doses of Aflibercept were given during this time period for wARMD in our practice. Most of the patients had been previously treated with other Anti-VEGF drugs. Most patients were treated with the other drugs at a regular interval to treat their disease, approximately every 4 to 6 weeks. Most patients responded favorably to Aflibercept given every 1 to 2 months. Several patients that had been treated frequently over a long time period with the other Anti-VEGF agents and were identified as limited or non-responders had prompt resolution of sub-retinal fluid and macular edema after 1 or 2 doses of Aflibercept. No cases of endophthalmitis or inflammation occurred.

CONCLUSION Our initial experience with Aflibercept for the treatment of wet ARMD is favorable and appears to be consistent with the results reported in the View 1 and 2 trials. There were several patients who had limited response previously to other anti-VEGF drugs and responded well when switched to Aflibercept.

TAKE HOME MESSAGE Aflibercept is well tolerated and effective for wet Age Related Macular Degeneration.

2:19 PM

Improvement in Diabetic Retinopathy (DR) Associated With 0.2 µg/d Fluocinolone Acetonide (FA) Treatment for Chronic Diabetic Macular Edema (DME)



- Pravin U. Dugel, MD

OBJECTIVE To demonstrate the improvements in visual acuity and diabetic retinopathy in patients with chronic diabetic macular edema treated with 0.2µg/d FA over 36 mo.

PURPOSE To demonstrate the improvements in visual acuity and diabetic retinopathy in patients with chronic diabetic macular edema treated with 0.2µg/d FA over 36 mo.

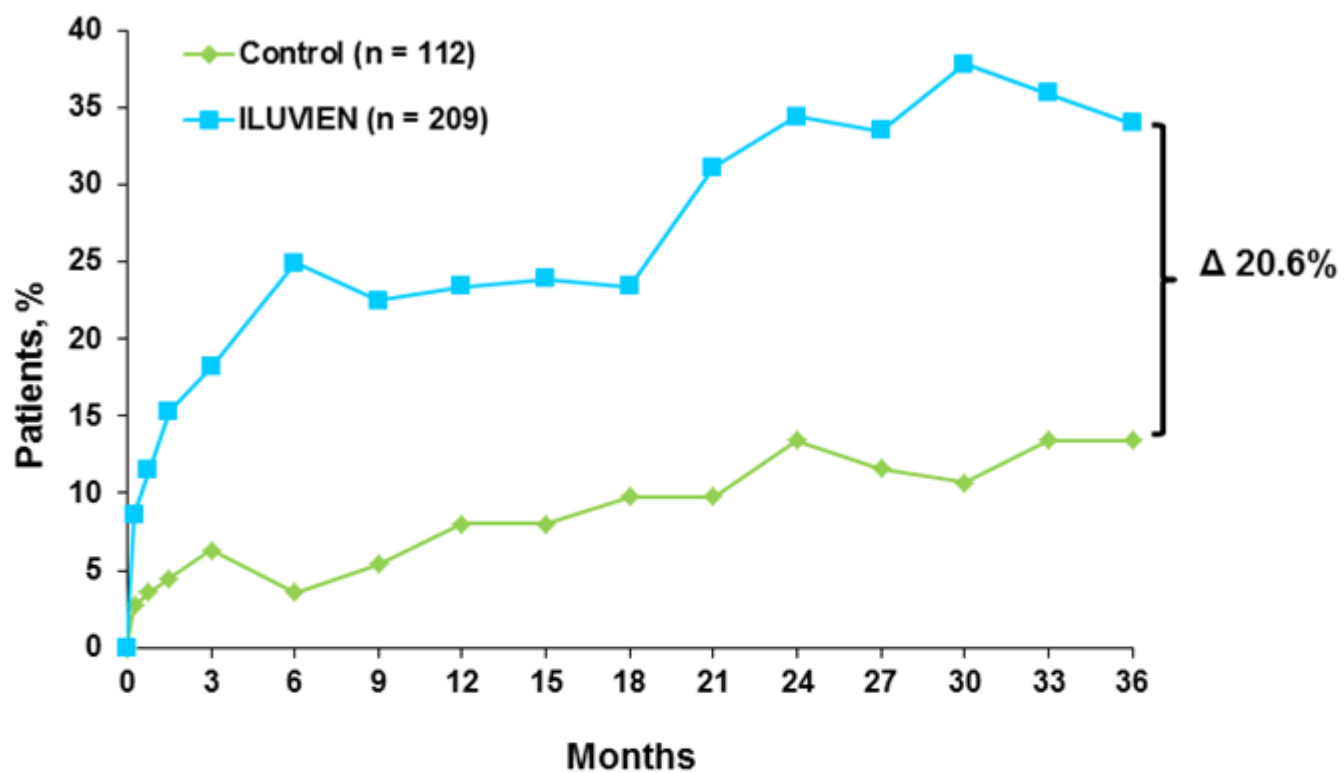
METHODS FAME consisted of 2 randomized, prospective, multicenter, double-masked, sham-controlled, parallel group, 36 mo phase 3 trials that enrolled pt with DME who

had prior macular laser treatment. Pts (n=956) were randomized to 0.2µg/d FAc (n=376), 0.5µg/d FA (n=395) or sham injection control (n=185). All pts were eligible for rescue laser treatment after wk 6 at masked investigator discretion and retreatment with study drug after mo 12 per prespecified criteria. Primary endpoint was pts gaining ≥15 letters VA at mo 24. Prespecified subgroups were analyzed for benefit/risk. DR was assessed by a masked reading center using 7 field color fundus photography graded by the ETDRS multistep eye scale.

RESULTS The FAME study met its primary endpoint - significantly more pts treated with 0.2µg/d FA experienced a ≥15-letter improvement in VA at mo 24 than control pts (28.7% vs 16.2%. $P=.002$). This significant benefit continued to mo 36. Over 36 mo, only 1 FA insert was needed by 74.4% of pts in the 0.2µg/d FA group. The most significant treatment effect was seen in pts with chronic DME, with 34.0% of FA-treated pts and 13.4% of control pts achieving a ≥15-letter improvement in BCVA undefined. Retinal thickness decreased over time in all groups. Among pts with chronic DME, 16.7% of 0.2µg/d FA treated pts and 8.3% of control pts experienced a ≥2-step improvement in DR ($P=0.42$) at mo 36. Cataract surgery was performed in 80.0% of phakic pts in the 0.2µg/d FA group and 27.3% of phakic controls by mo 36. Incisional IOP-lowering surgery was required by 4.8% of 0.2µg/d FA treated pts and 0.5% of control pts by mo 36.

CONCLUSION Treatment with 0.2µg/d FA in pts with DME led to rapid & sustained improvements in VA for up to 36 mo w/o the need for frequent injections. The treatment effect was most significant in pts with chronic DME. These pts also experienced significant improvement in DR with 0.2µg/d FA treatment compared with control. 0.2µg/d FA was well tolerated with a low rate of incisional IOP-lowering procedures.

TAKE HOME MESSAGE 0.2µg/d FA treatment led to rapid & sustained improvements in VA for up to 36 mo in pts with DME, particularly those with chronic DME. Chronic DME pts also experienced significant improvement in DR.



2:27 PM

Visual and Anatomic Outcomes of Anti-VEGF Therapy in Exudative AMD and Vitreomacular Interface Disease



- Sophie Jane Bakri, MD
- Amy E Green-Simms, MD
- Blake M Fechtel
- Zubin Agarwal, MPH

OBJECTIVE To describe clinical and imaging features and number of injections in eyes with and without vitreomacular interface disease treated with intravitreal anti-VEGF injections for wet AMD

PURPOSE To describe clinical and imaging features of eyes with and without vitreomacular interface disease (VMID) treated with intravitreal anti-VEGF injections for exuative age-related macular degeneration (AMD), followed over an average of 2.5 years.

METHODS Retrospective, interventional case series involving 32 eyes with VMID and 146 eyes without traction. Best corrected visual acuity (BCVA), manually-measured central foveal thickness from optical coherence tomography imaging, and the number and timing of intravitreal anti-VEGF injections were reviewed.

RESULTS Eyes with VMID and exudative AMD received more intravitreal injections (mean 14.7) over four years than eyes without traction (mean 9.5) ($p=0.0224$). Eyes with VMID had similar BCVA to eyes without traction at baseline ($p=0.8013$) and years 1 through 4 ($p=0.5417, 0.6275, 0.4574, 0.0570$ respectively). Best BCVA showed significant improvement over baseline BCVA in eyes with (logMAR 0.67 to 0.47, $p=0.0182$) and without (logMAR 0.61 to 0.44, $p=0.0001$) VMID. Central foveal thickness was similar to eyes without traction at baseline and years 1 through 3, and declined over time in eyes with VMID.

CONCLUSION In eyes with VMID, anti-VEGF therapy resulted in improved BCVA and decreased central foveal thickness despite continued vitreomacular traction. Eyes with VMID required more intravitreal anti-VEGF agents than eyes without VMID.

TAKE HOME MESSAGE In eyes with vitreomacular interface disease, anti-VEGF therapy resulted in improved BCVA and decreased central foveal thickness despite continued vitreomacular traction.

2:35 PM

Quantitative Determination and Comparison of Intravitreal Cytokines in DRP, RVO and ARMD



- Michael J. Koss, MD
- Frank H.J. Koch, MD
- Pankaj Singh, MD

OBJECTIVE To illustrate the different levels of vitreal cytokines in the three major retinal vascular diseases

PURPOSE To determine inflammatory and angiogenetic cytokine levels from undiluted vitreous of patients with diabetic retinopathy (DRP), retinal vein occlusion (RVO) and exsudative age-related macular degeneration (ARMD) and compare them with clinical and anatomic changes.

METHODS 187 patients (median age 67.0 years, 101 male) underwent an intravitreal combination therapy, including a single-site 23-gauge core vitrectomy and the application of bevacizumab, dexamethasone and triamcinolone in RVO (n=80) and DRP (n=70), or bevacizumab, dexamethasone and SF-6-gas in ARMD (n=12). Vitreous samples were obtained before drug application and stored at -80°C. To describe the inflammatory processes we analyzed Interleukin-6 (IL-6) and monocyte chemoattractant protein-1 (MCP-1), for angiogenetic activity we determined intravitreal

vascular endothelial growth factor (VEGF-A) levels. Vitreous samples from patients with vitreous floaters served as controls (n=25).

RESULTS Compared to the control all cytokine levels were significant elevated in ARMD, RVO and DME. Only VEGF in ARMD did not show a significant difference. In DRP samples of patients with diffuse diabetic macula edema (DME) had statistically significant higher VEGF-A and MCP-1 levels than patients with focal DME. Ischemic DRP had significant higher VEGF levels than non-ischemic DRP. All measured cytokines were significantly higher in central retinal vein occlusion (CRVO) than in branch retinal vein occlusion (BRVO). ARMD showed the highest median of MCP-1 of all three entities.

CONCLUSION We could demonstrate that intravitreal cytokine levels significantly differ in DRP, RVO and ARMD and that these differences are partly depending on clinical-anatomical changes (e.g. grade of ischemia). The depicted specific characteristic dysregulation of inflammatory and angiogenetic cytokines could allow for more targeted future therapies.

TAKE HOME MESSAGE

The depicted specific characteristic dysregulation of inflammatory and angiogenetic cytokines could allow for more targeted future therapies.